

## Anomalies that Should Not Be Missed by Ultrasound

Frank A. Chervenak, MD

 **New York Weill Cornell Medical Center**  
Weill Cornell Medical College  
New York-Presbyterian Hospital



Ian Donald University  
Ho Chi Minh City, Vietnam  
March 2011

1

## The Ultrasound Diagnosis of Fetal Anomalies: An Overview

- Absence of a normally present structure
- Presence of an additional structure
- Herniation through a structural defect
- Dilation behind an obstruction
- Abnormal biometry
- Abnormal fetal motion

2

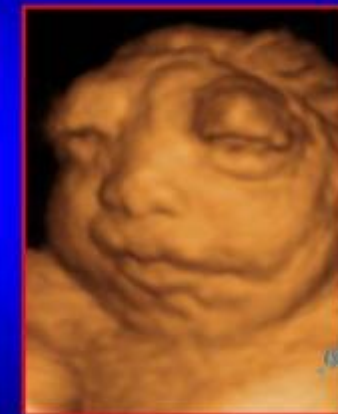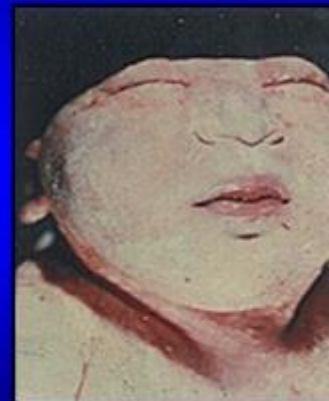## The Ultrasound Diagnosis of Fetal Anomalies: An Overview

- Absence of a normally present structure
- Presence of an additional structure
- Herniation through a structural defect
- Dilation behind an obstruction
- Abnormal biometry
- Abnormal fetal motion

3

### Anencephaly

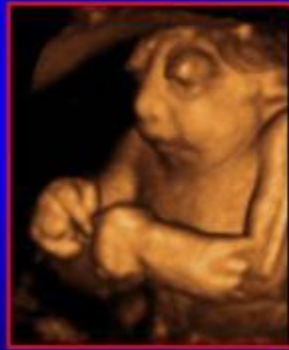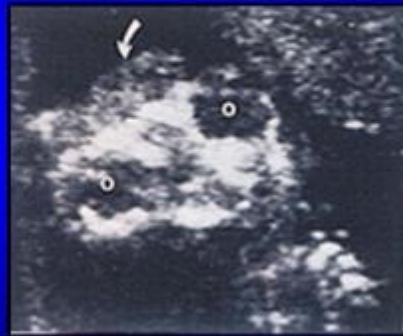Absence of calvaria and underlying brain



4

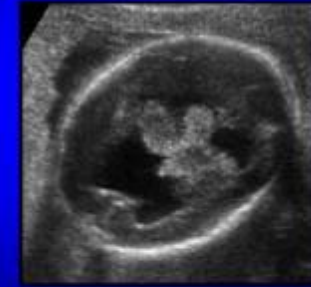
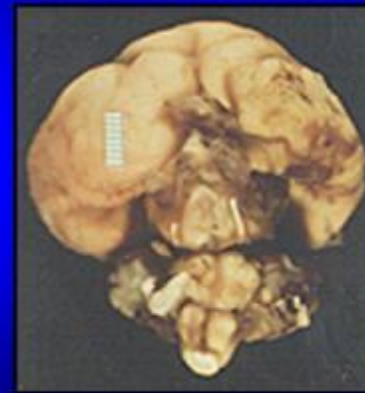## Anencephaly

### Ultrasound Diagnosis

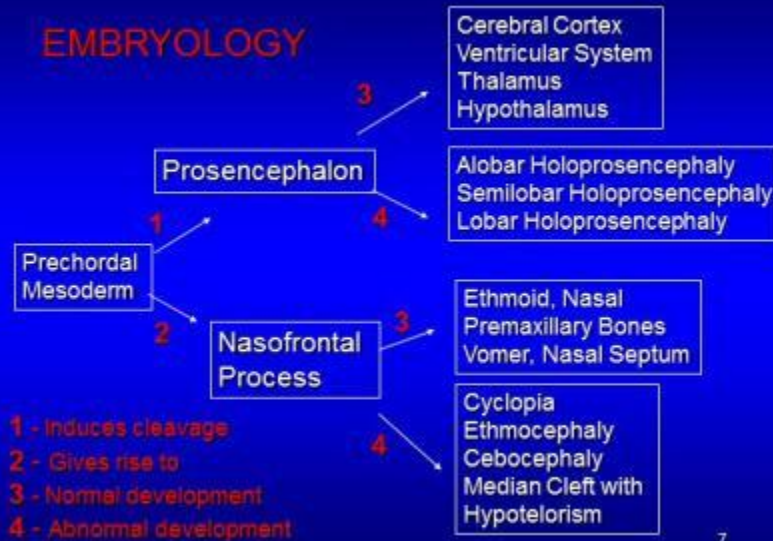


5

## Arrhinencephaly/Holoprosencephaly

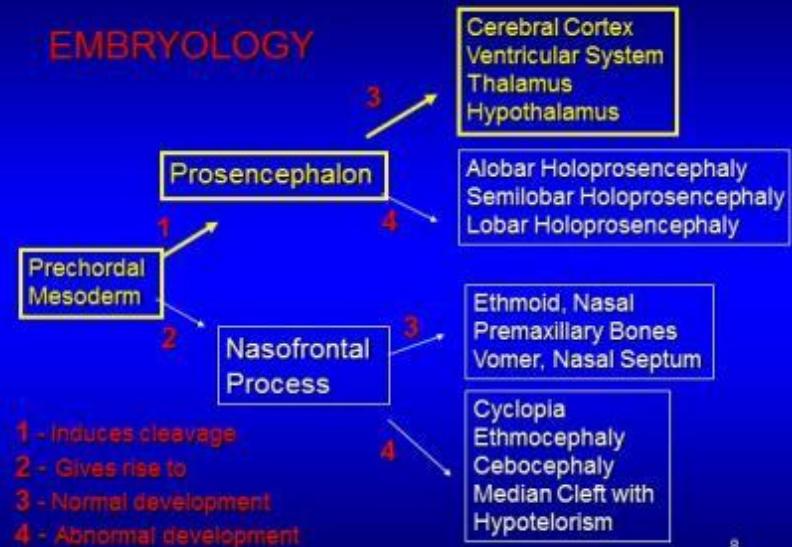


### EMBRYOLOGY



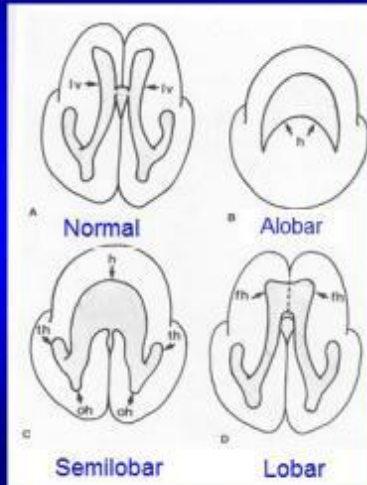
7

### EMBRYOLOGY



8

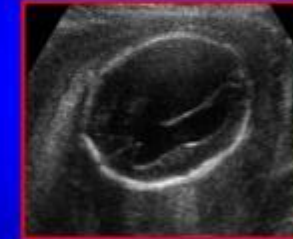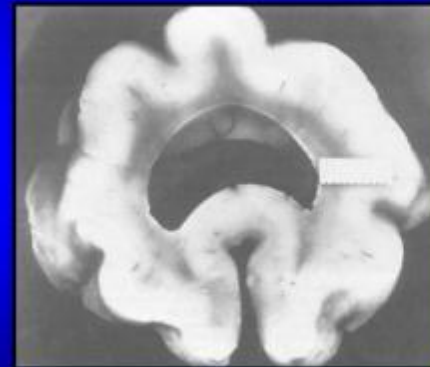
## Holoprosencephaly



Absence of midline cerebral structures resulting from incomplete cleavage of the primitive forebrain

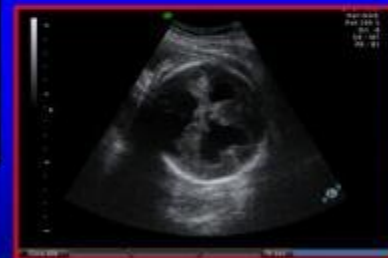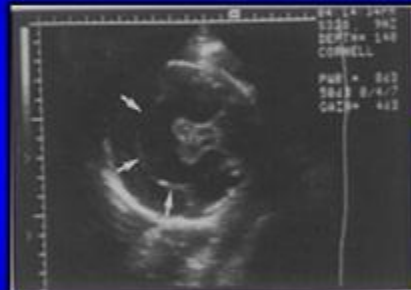9

## Holoprosencephaly



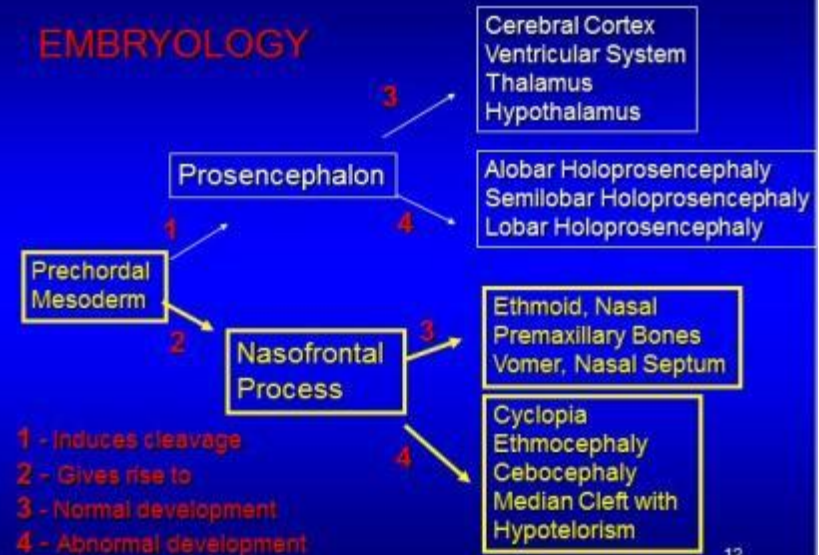
10

## Holoprosencephaly



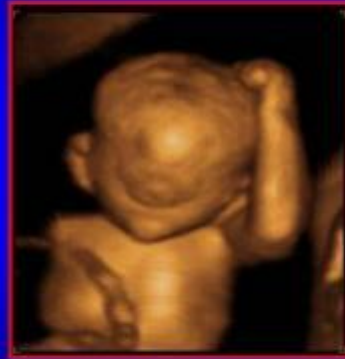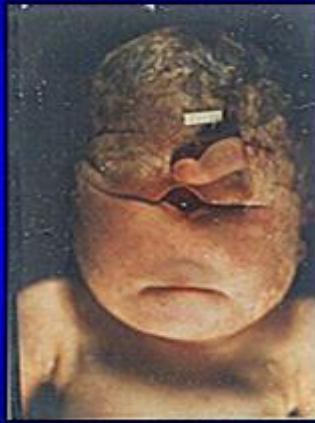11

## EMBRYOLOGY



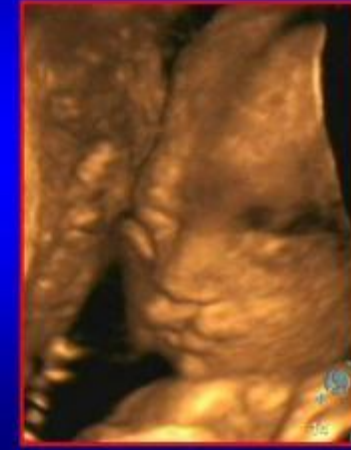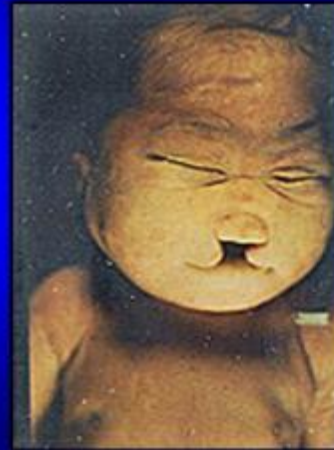12

## Cyclopia

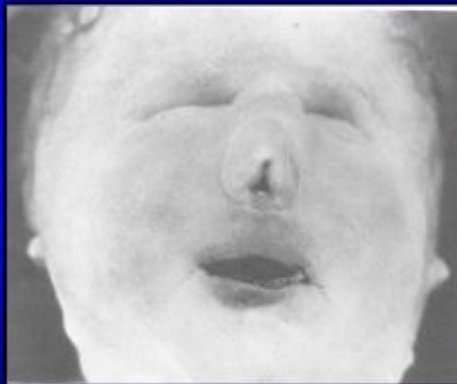

13

## Midline Facial Cleft with Hypotelorism



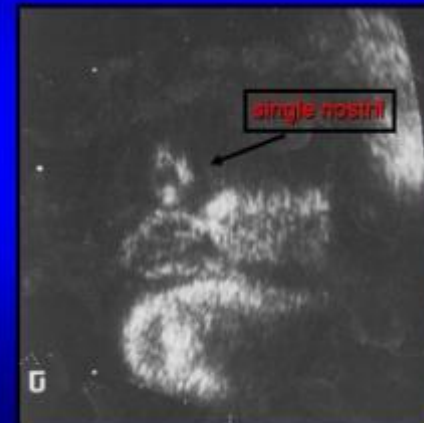
## Cebocephaly



- Hypotelorism
- Normally placed nose
- Single nostril

15

## Cebocephaly Ultrasound Diagnosis



16

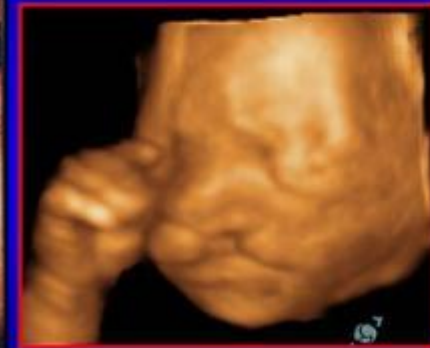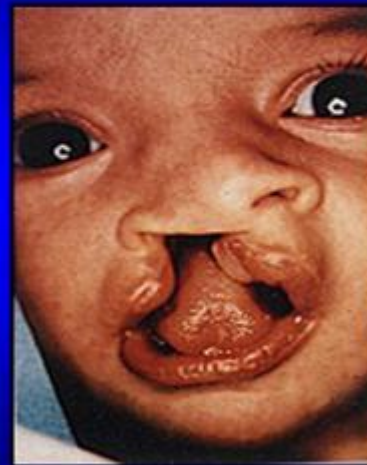## Holoprosencephaly

### Risk Factors

- Maternal diabetes
- Family history of holoprosencephaly
- Adults with mild manifestations of dominantly inherited holoprosencephaly

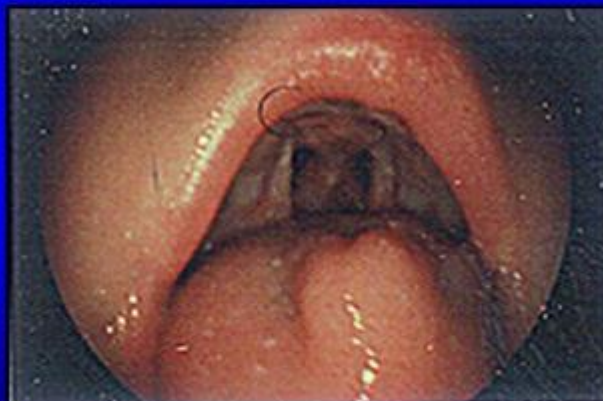17

## Cleft Lip and Palate



18

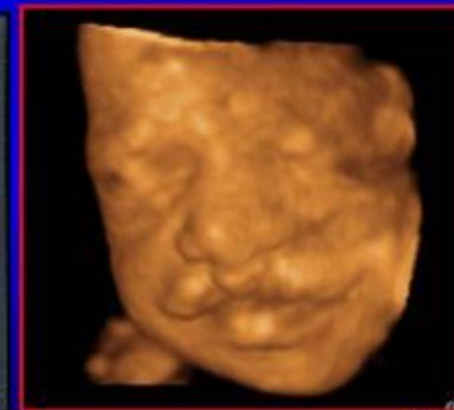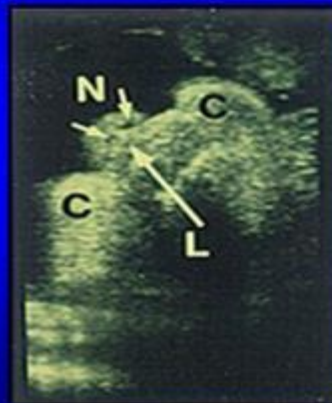
## Cleft Palate



19

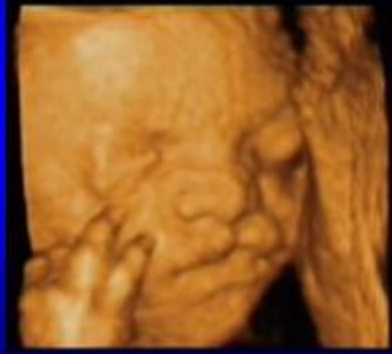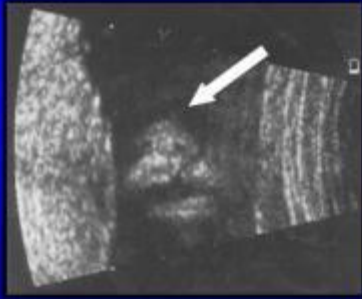## Fetal Lip

### Ultrasound Assessment



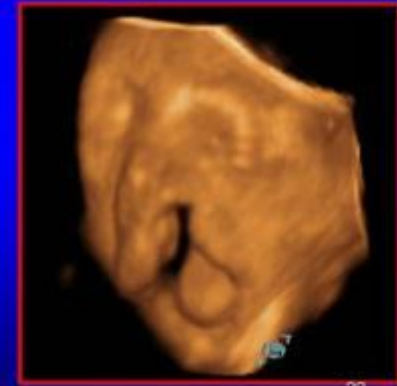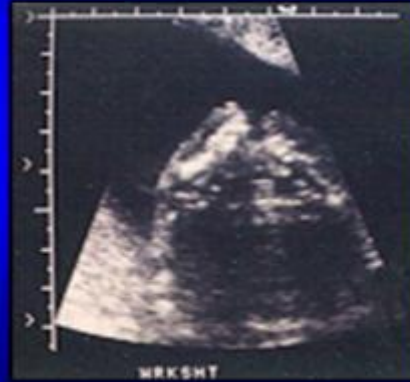20

## Cleft Lip Ultrasound Diagnosis



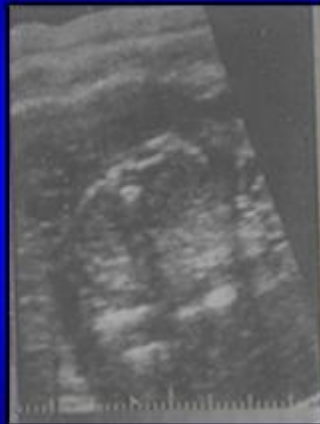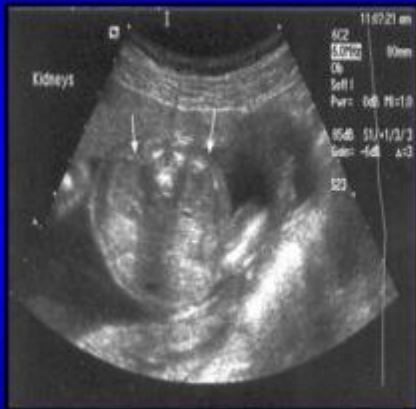21

## Cleft Lip and Palate Ultrasound Diagnosis



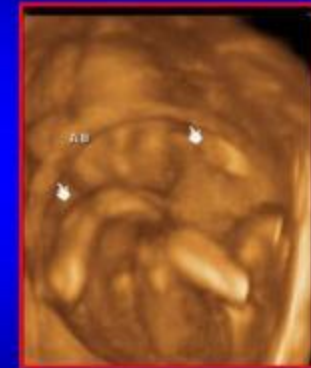
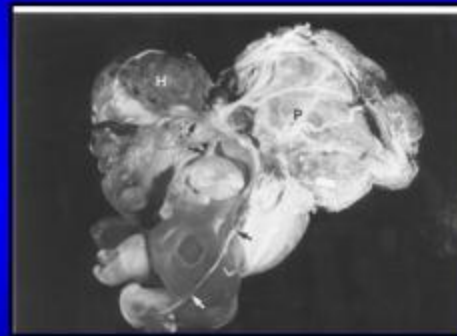
22

## Kidneys/Renal Agenesis



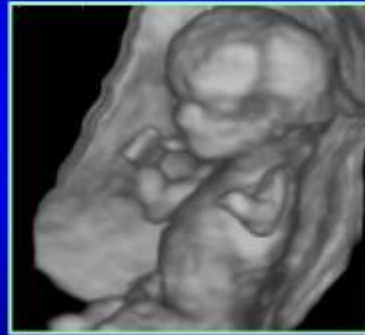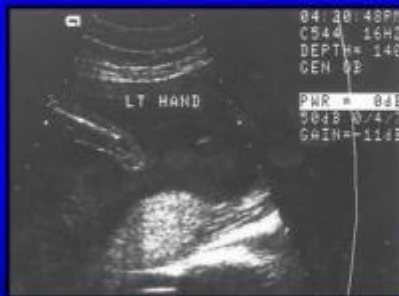23

## Amniotic Band Syndrome



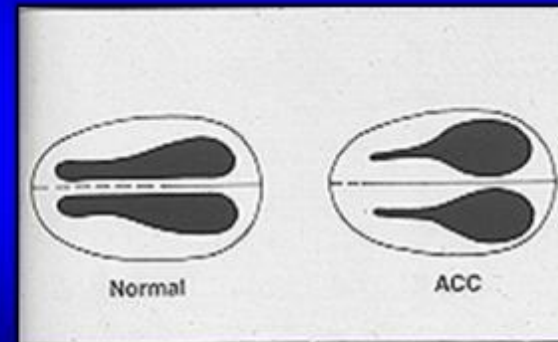
24

## Amniotic Band Syndrome



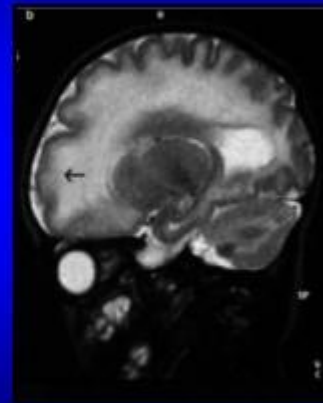
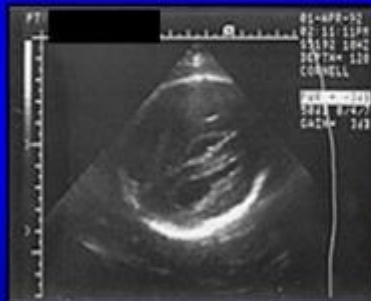25

## Agnesis of the Corpus Callosum



26

## Agnesis of the Corpus Callosum



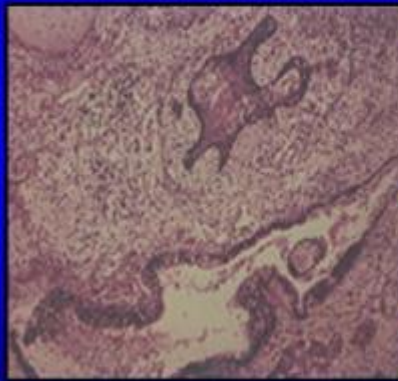
27

## The Ultrasound Diagnosis of Fetal Anomalies: An Overview

- Absence of a normally present structure
- Presence of an additional structure
- Herniation through a structural defect
- Dilation behind an obstruction
- Abnormal biometry
- Abnormal fetal motion

28

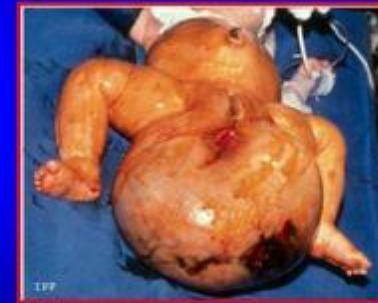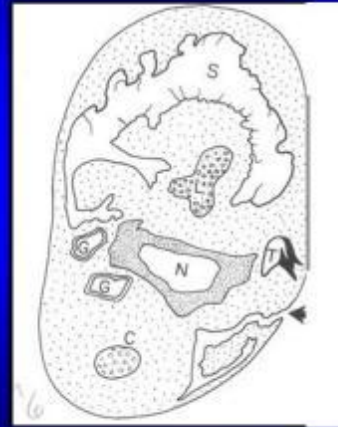## Fetal Teratomas



- Most common neoplasm of newborns
- Derived from pluripotent cells
- Composed of solid and cystic areas

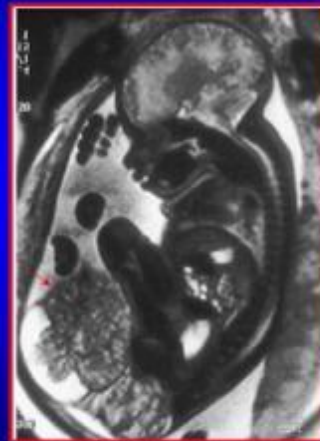
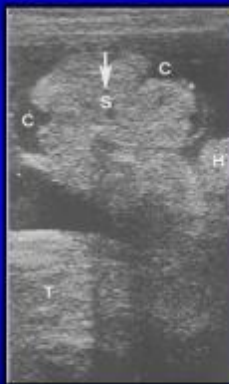29

## Teratoma



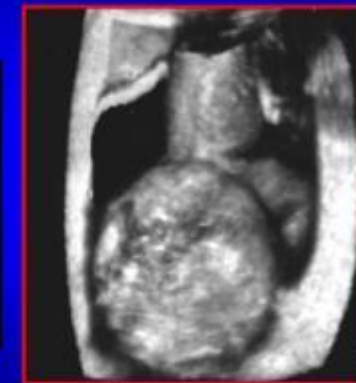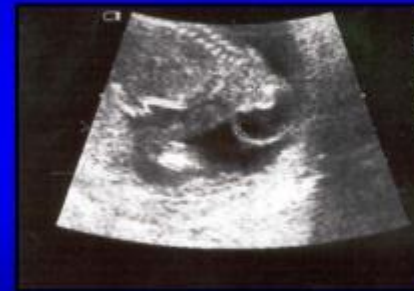30

## Teratoma



31

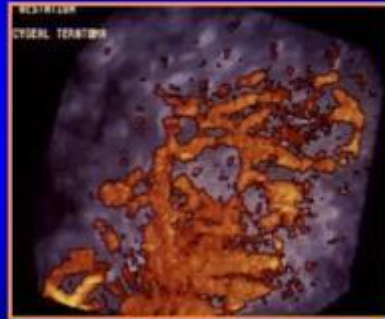
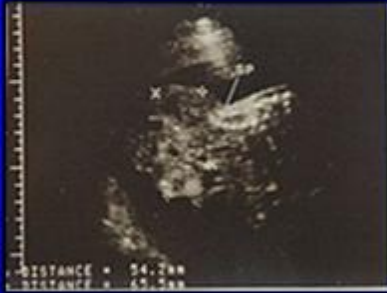## Sacroccocygeal Teratoma



32

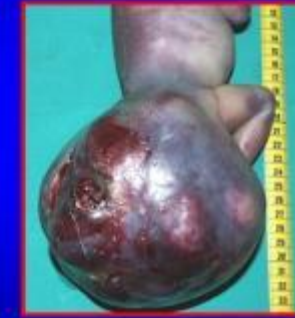
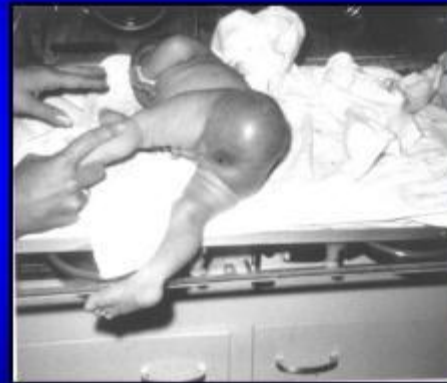
## Sacroccygeal Teratoma



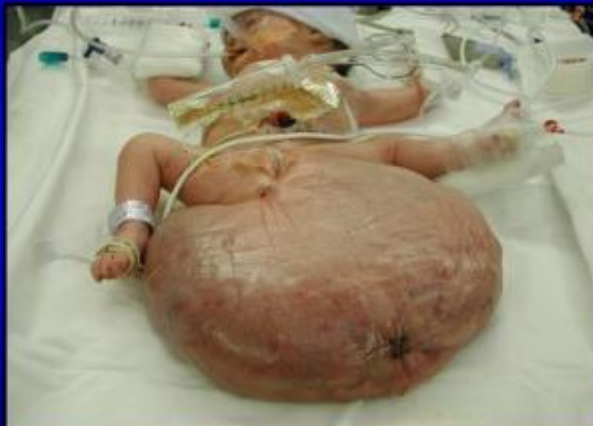33

## Sacroccygeal Teratoma



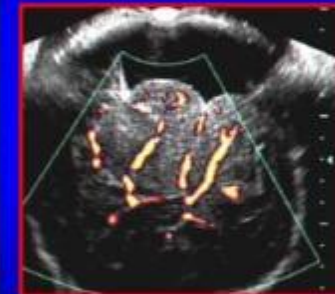
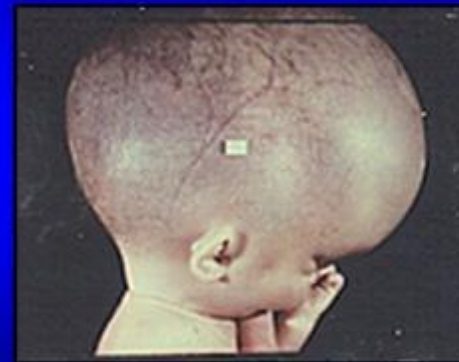34

## Sacroccygeal Teratoma



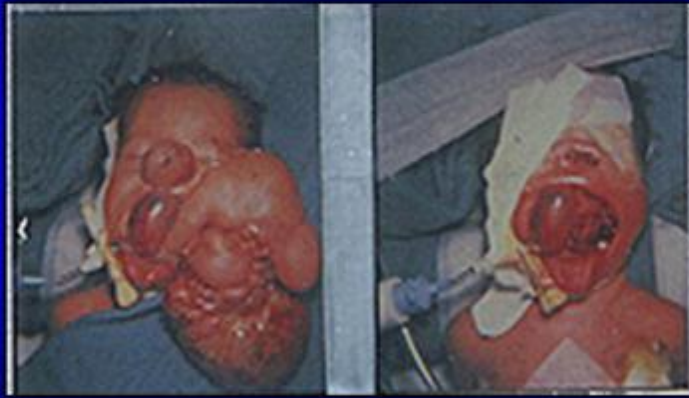
35

## Intracranial Teratoma



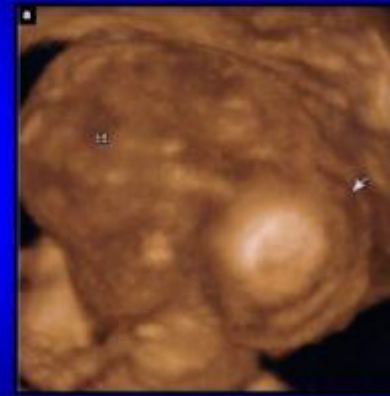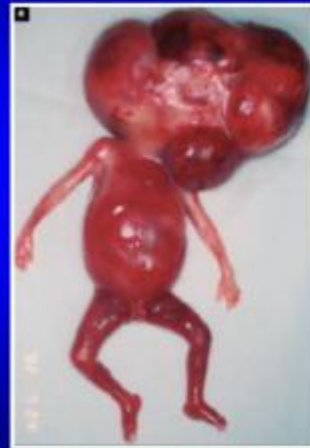36

## Epignathus



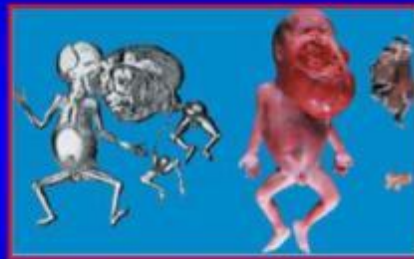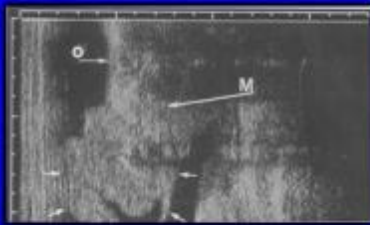
37

## Epignathus



38

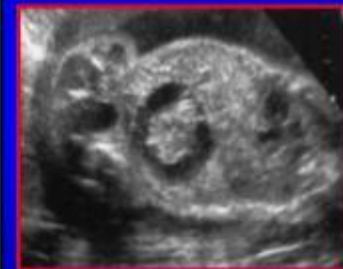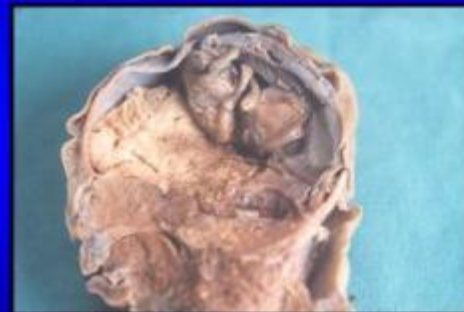## Epignathus



39

## Fetal Teratomas

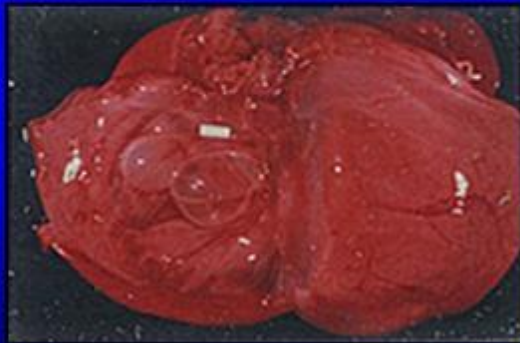
*Fetus-in-Fetu*



40

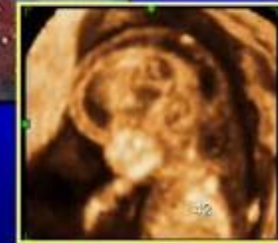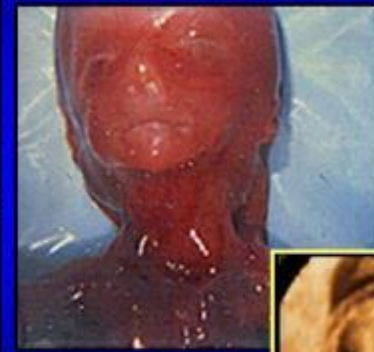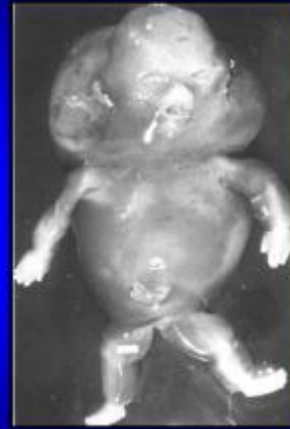## Fetal Cystic Hygroma

Fluid-filled protrusions arising from abnormal development of the lymphatic system

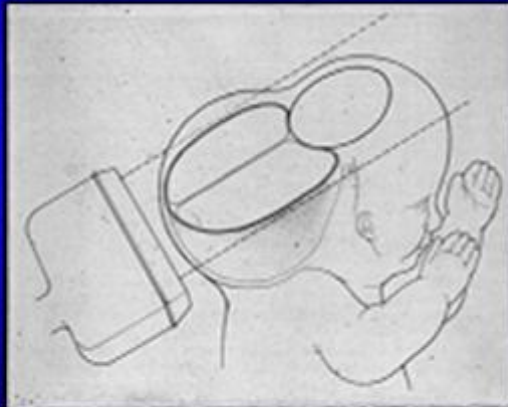


41

## Cystic Hygroma

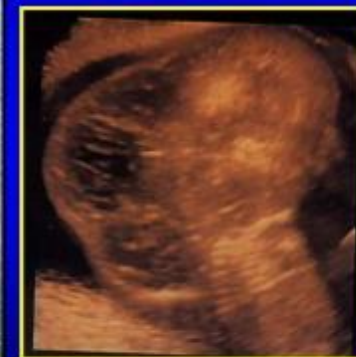
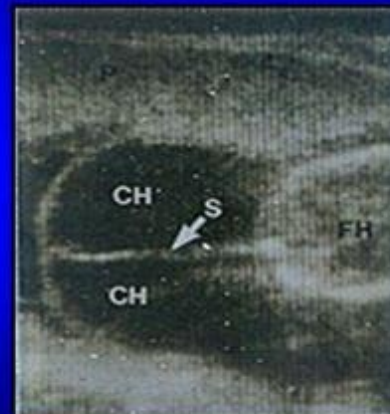
## Fetal Cystic Hygroma



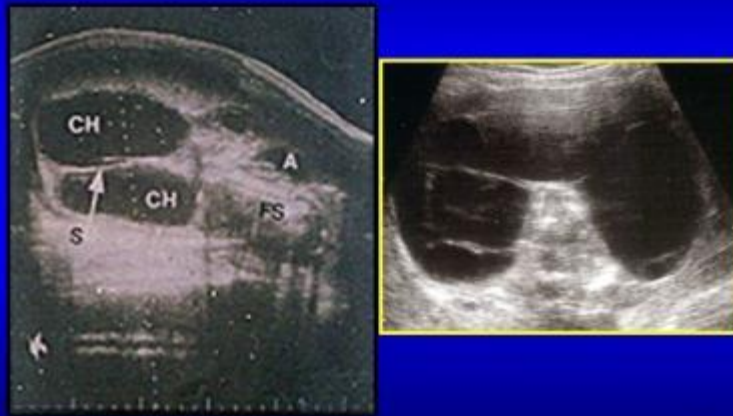43

## Fetal Cystic Hygroma



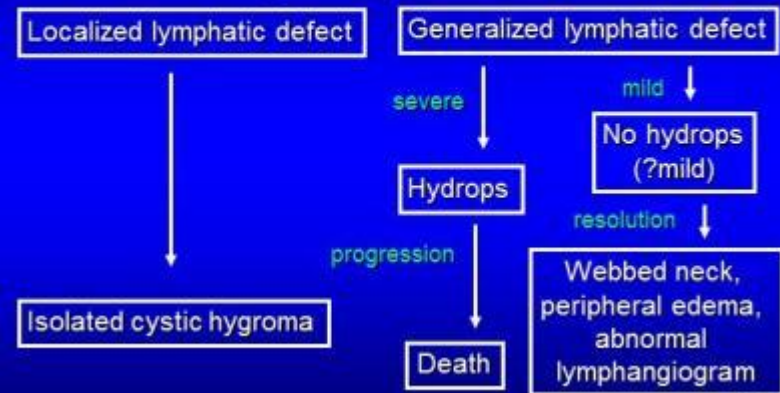
44

## Fetal Cystic Hygroma



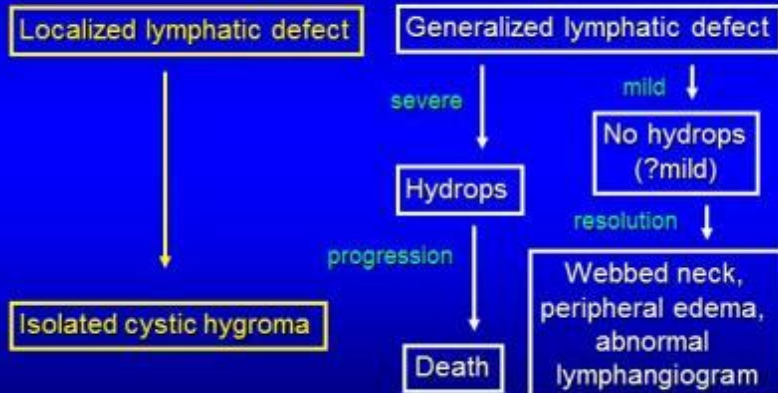
45

## Fetal Cystic Hygroma



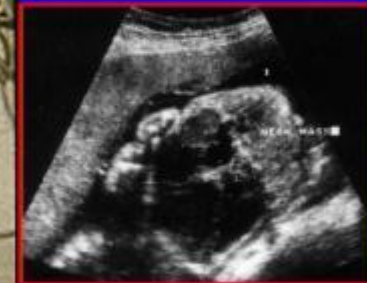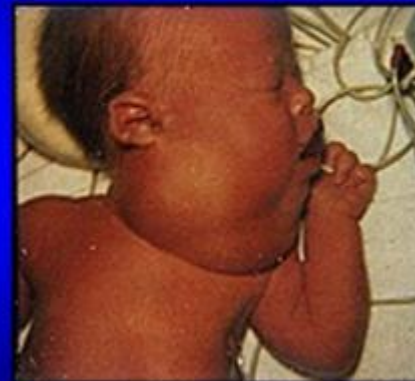46

## Fetal Cystic Hygroma



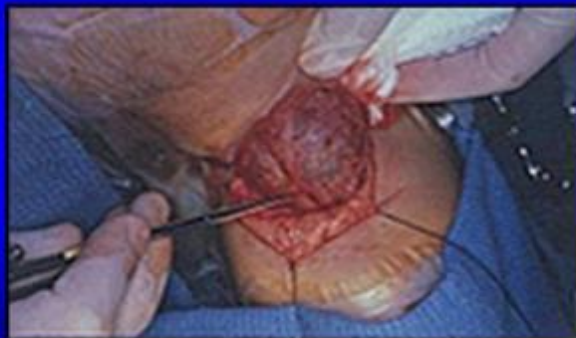47

## Cystic Hygroma



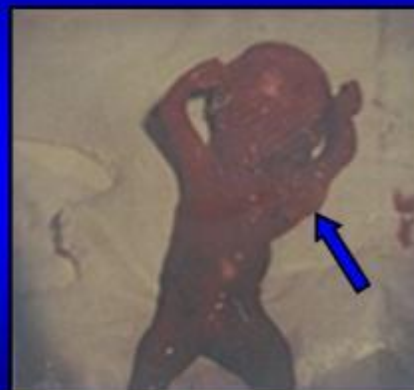
48

## Cystic Hygroma: Surgical Resection



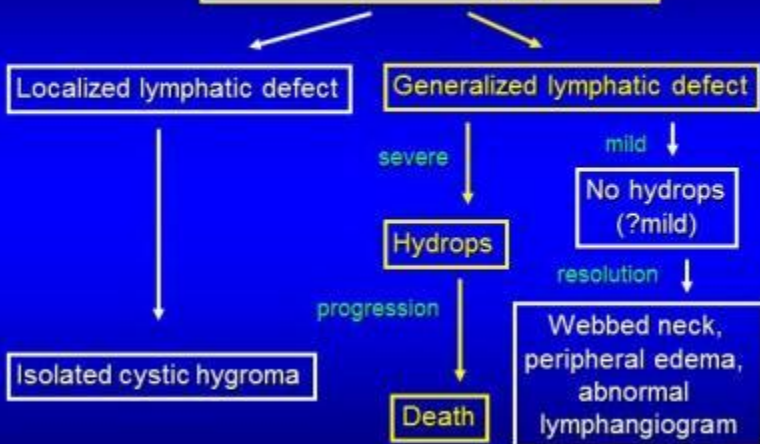
49

## Axillary Hygroma



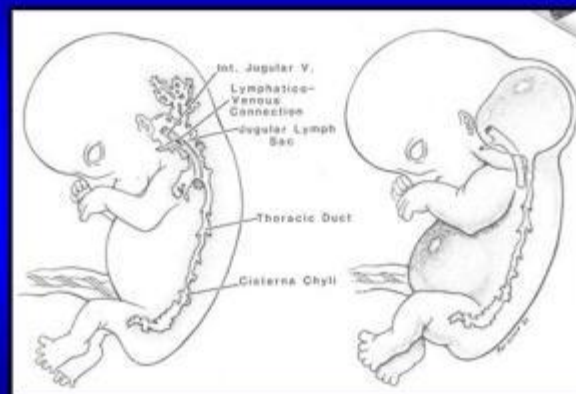
50

## Fetal Cystic Hygroma



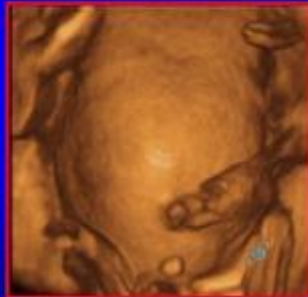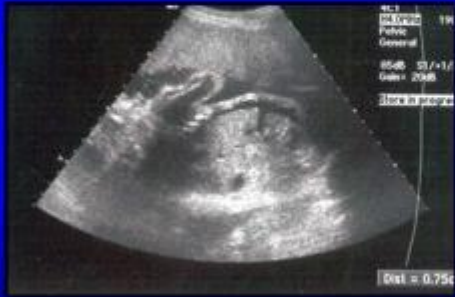51

## Cystic Hygroma



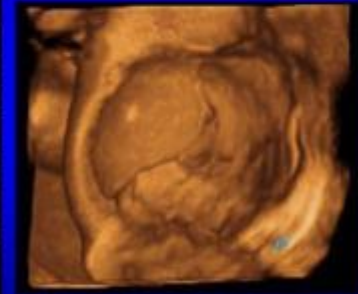
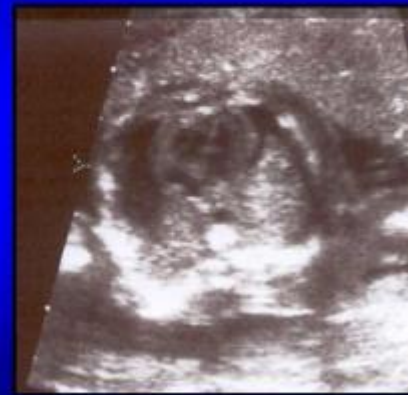52

## Hydrops Fetalis Fetal Ascites



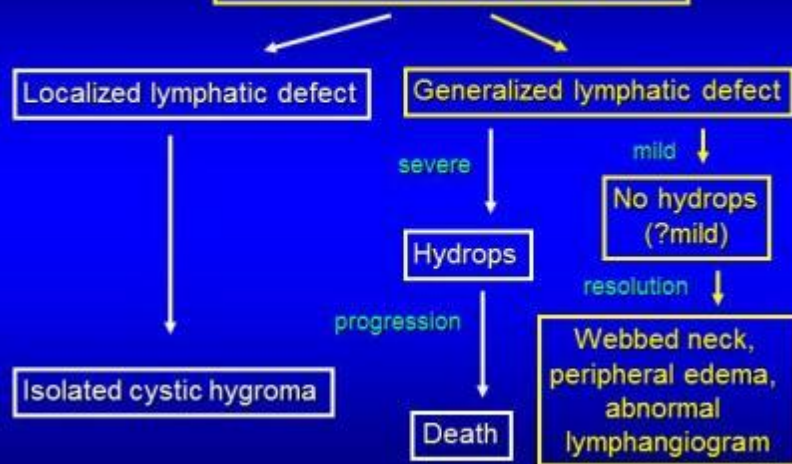
53

## Hydrops Fetalis Pleural Effusions



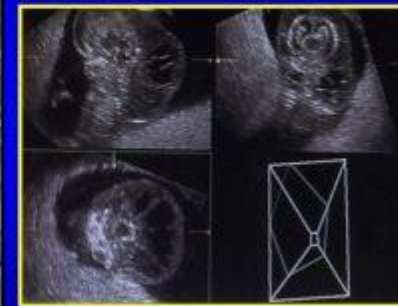54

## Fetal Cystic Hygroma



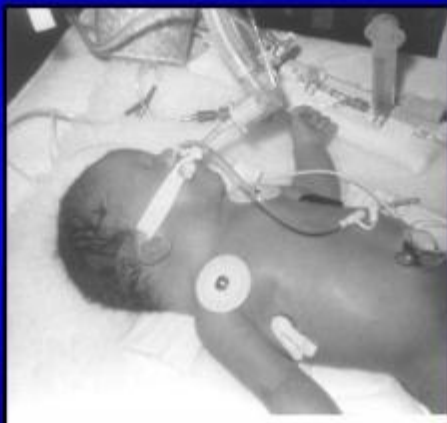55

## Cystic Hygroma



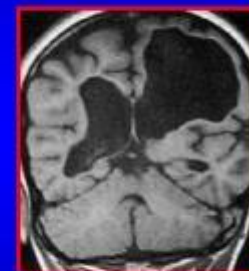
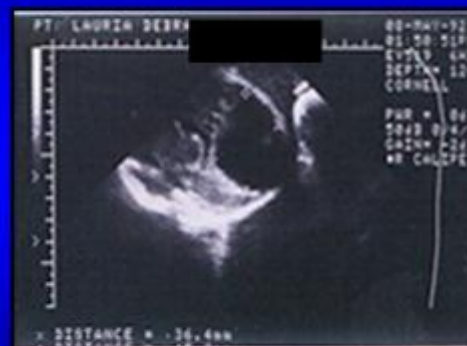56

## Cystic Hygroma



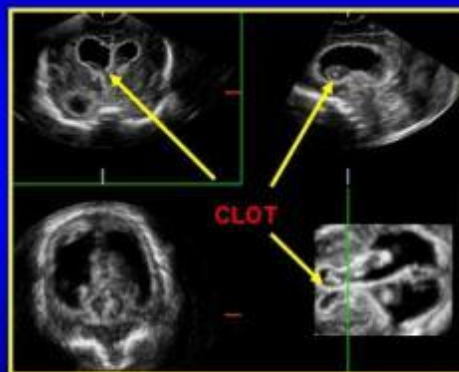
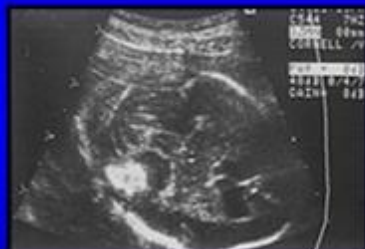57

## Porencephalic Cyst



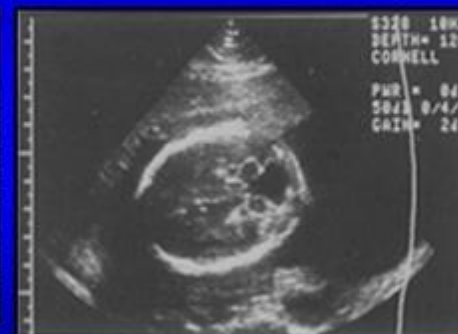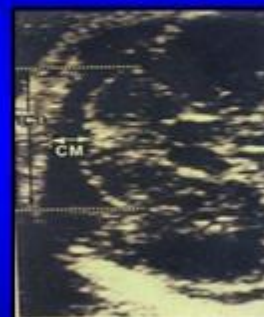58

## Intracranial Hemorrhage



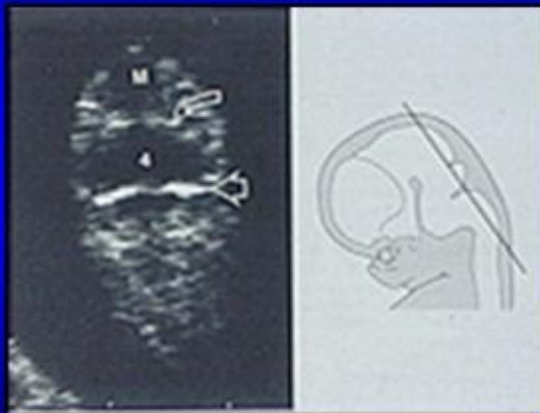
59

## Dandy Walker Malformation



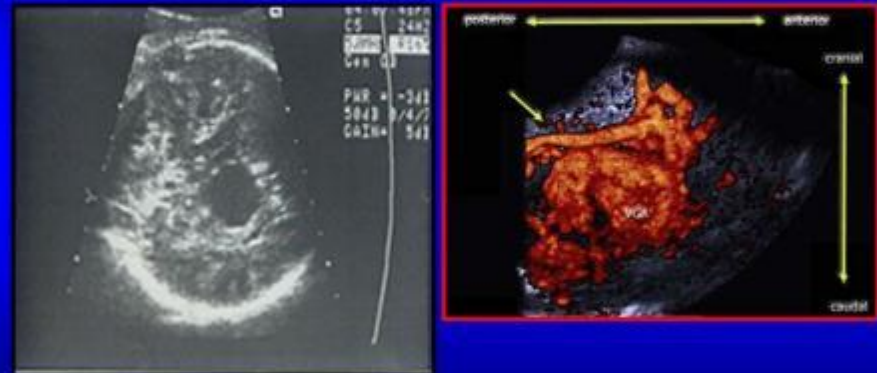60

## Rhombencephalon



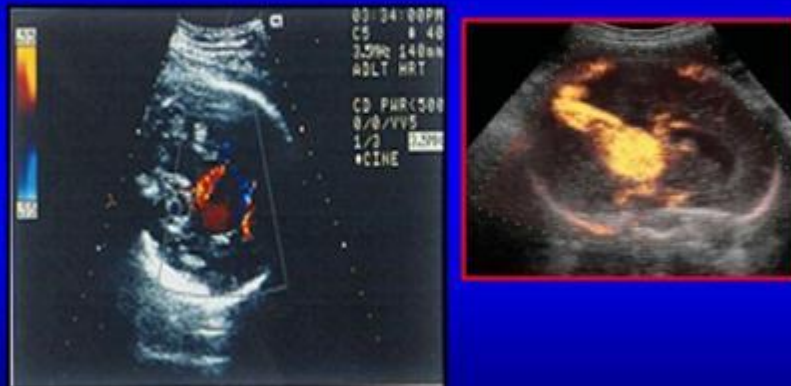
61

## Vein of Galen AVM



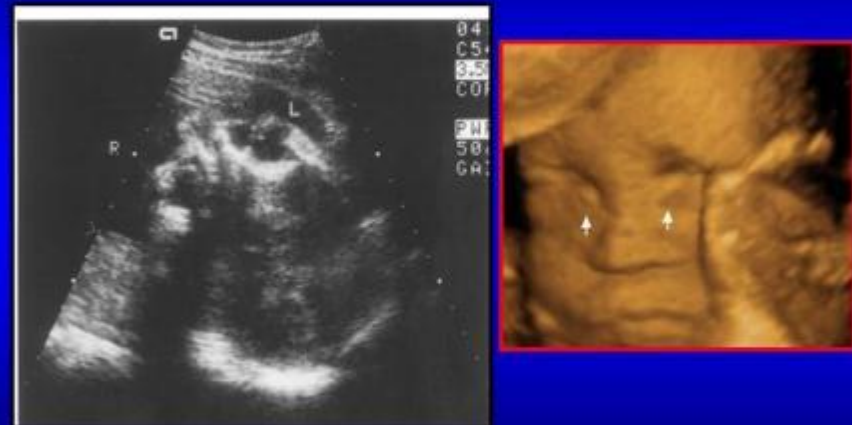62

## Vein of Galen AVM



63

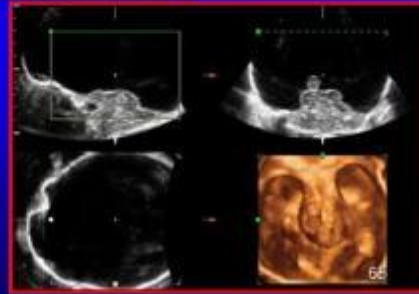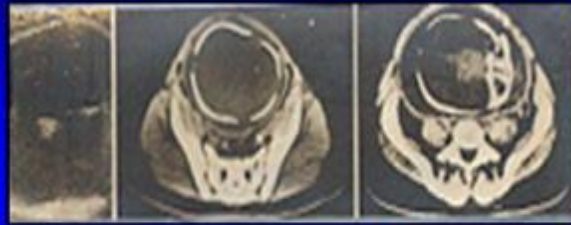
## Lacrimal Duct Cyst



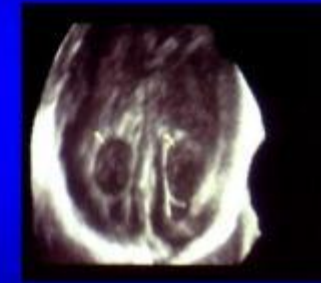
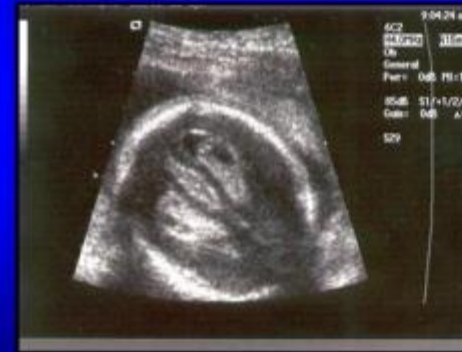64



## Hydranencephaly



## Choroid Plexus Cyst



66

## The Ultrasound Diagnosis of Fetal Anomalies: An Overview

- Absence of a normally present structure
- Presence of an additional structure
- Herniation through a structural defect
- Dilation behind an obstruction
- Abnormal biometry
- Abnormal fetal motion

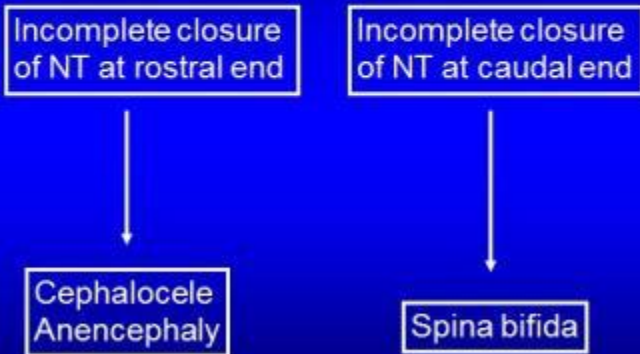
67

## Neural Tube Defects

- NT and overlying mesoderm begin closure in the region of the fourth somite
- Fusion extends rostrally and caudally during the fourth week of fetal life

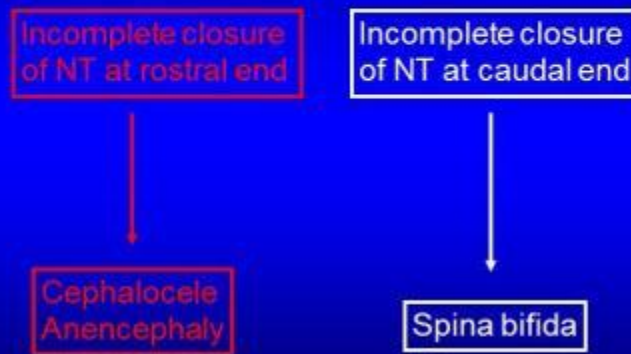
68

## Neural Tube Defects



69

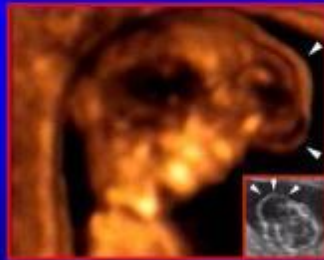
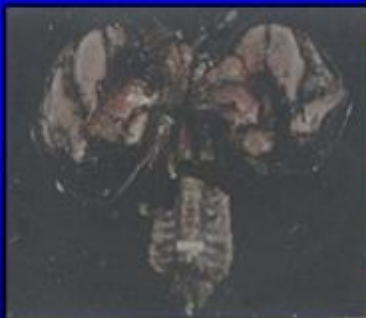
## Neural Tube Defects



70

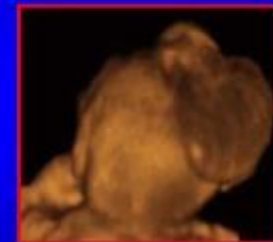
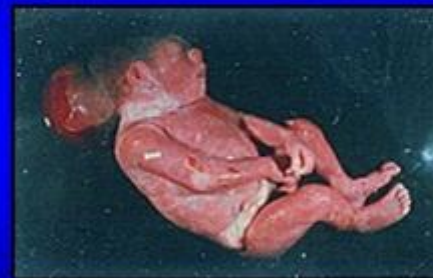## Cephaloceles

Herniation of meninges and frequently brain substance through a defect in the cranium



71

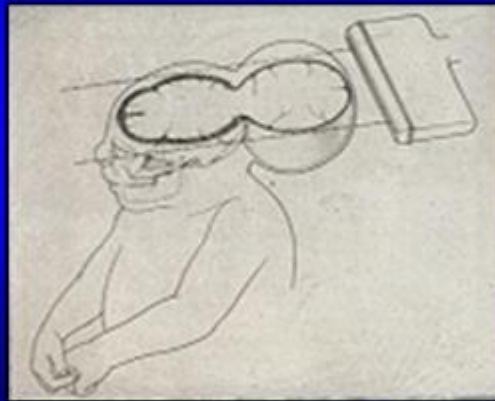## Encephalocele



72

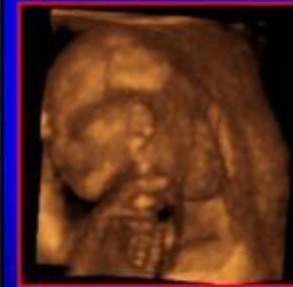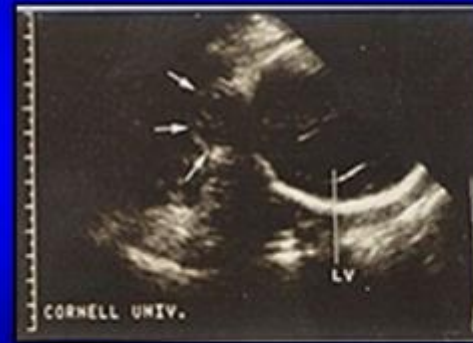## Cephaloceles

Ultrasound diagnosis



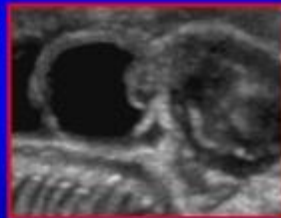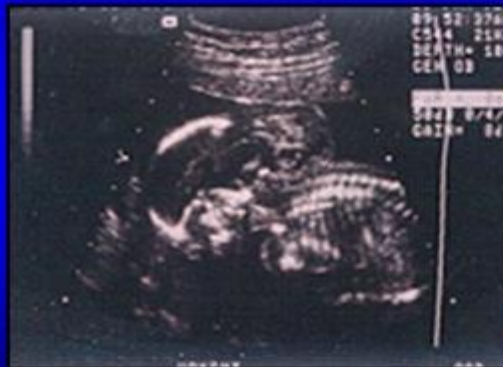73

## Encephalocele



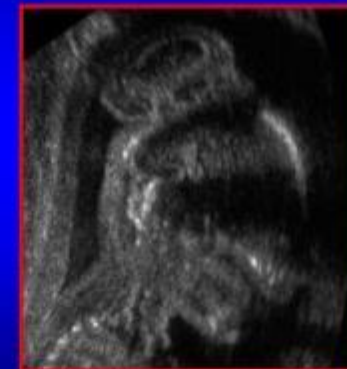
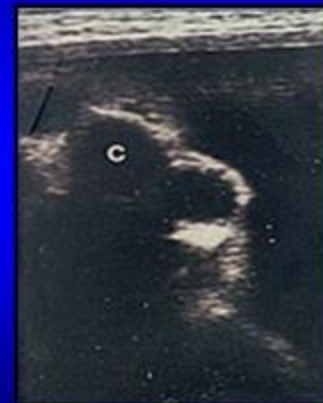74

## Encephalocele



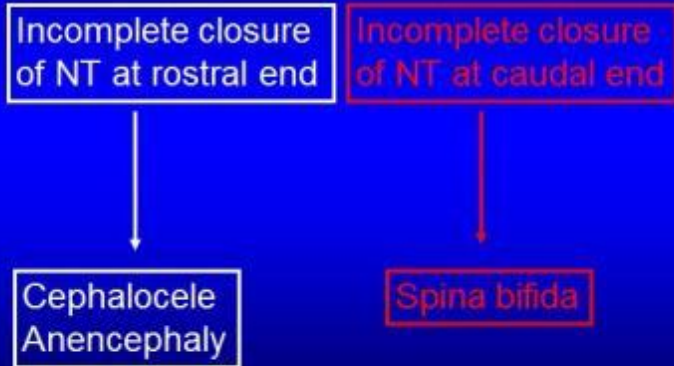
75

## Encephalocele



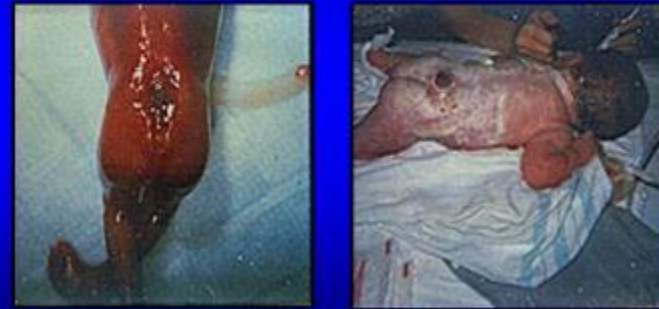76

## Neural Tube Defects



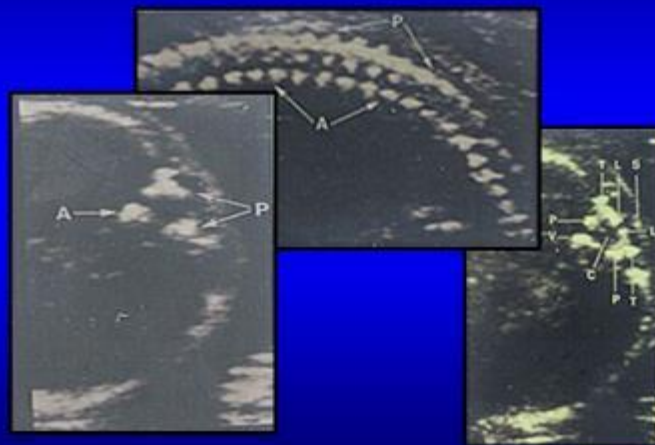
77

## Spina Bifida



78

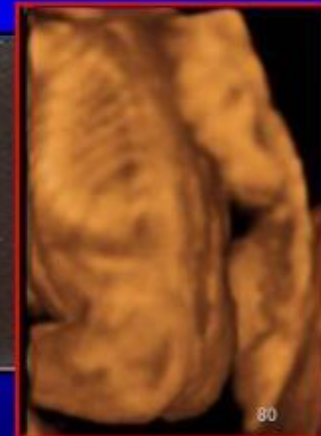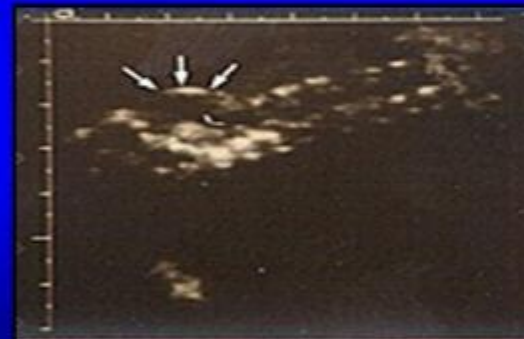
## Evaluating the Spine



79

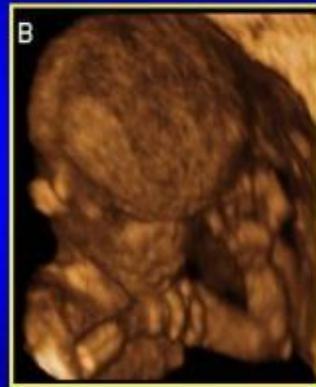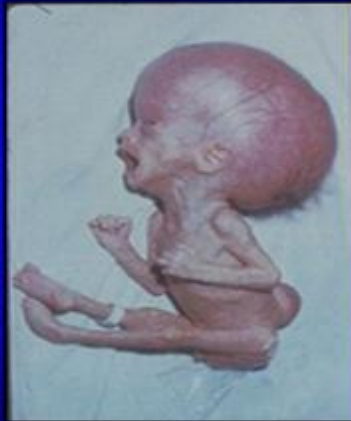## Spina Bifida

Failed fusion at the caudal end of NT with herniation



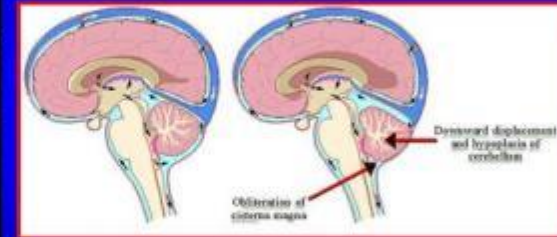
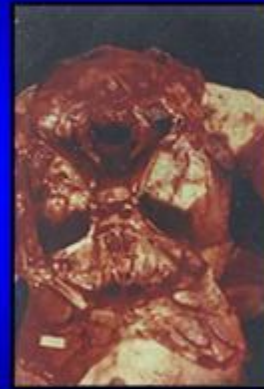80

## Hydrocephalus/Spina Bifida



81

## Arnold-Chiari Malformation



82

## Arnold-Chiari Malformation



83

## Arnold-Chiari Malformation



84

## Arnold-Chiari Malformation

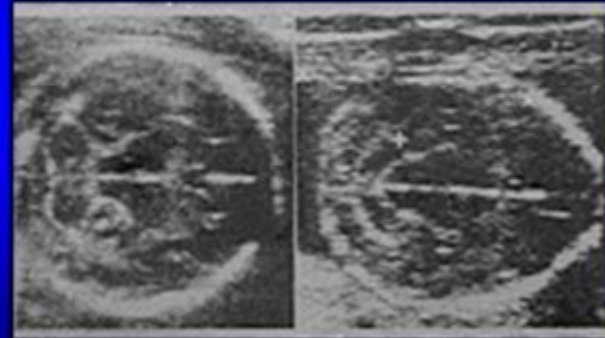
Lemon sign



85

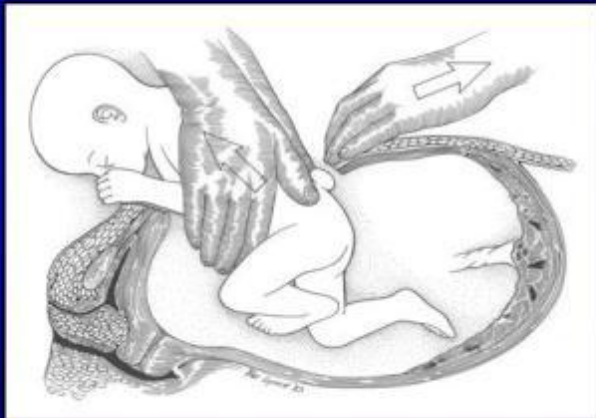
## Arnold-Chiari Malformation

Banana sign



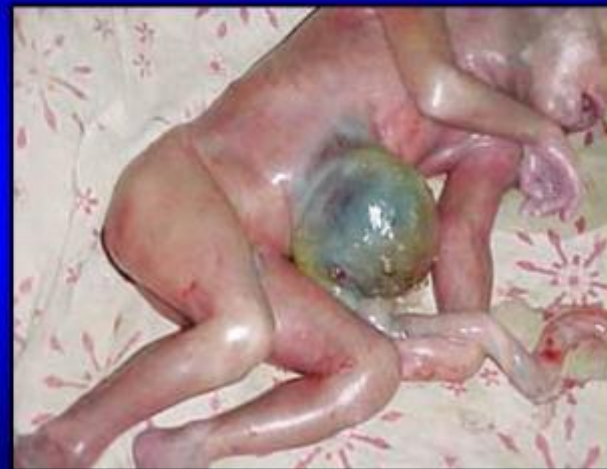86

## Neural Tube Defect: Delivery



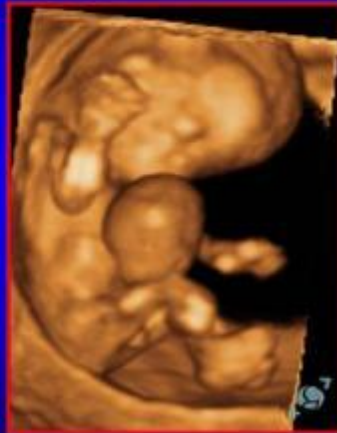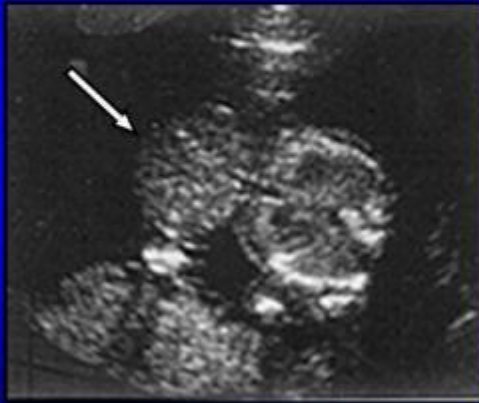87

## Omphalocele



88

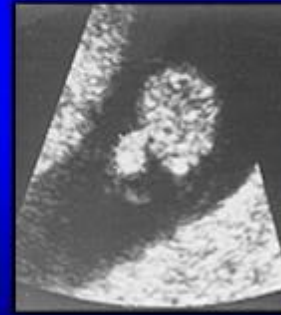## Omphalocele



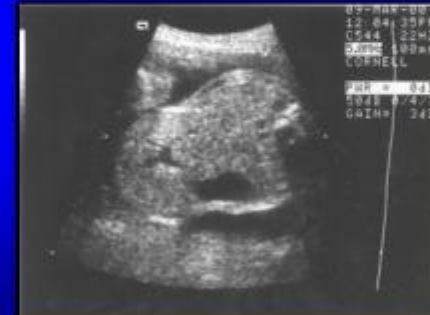89

## Omphalocele

Physiologic 1st  
midgut herniation

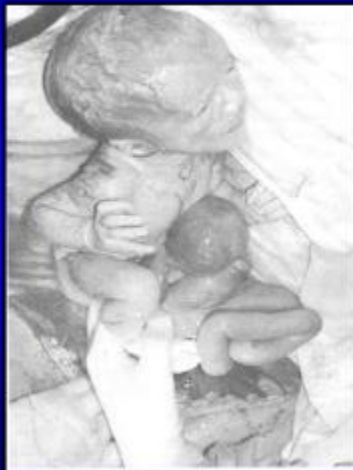

Abnormal herniation of  
abdominal contents



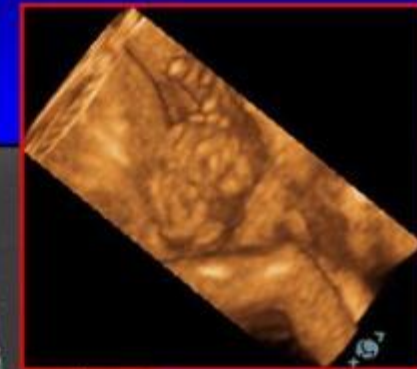
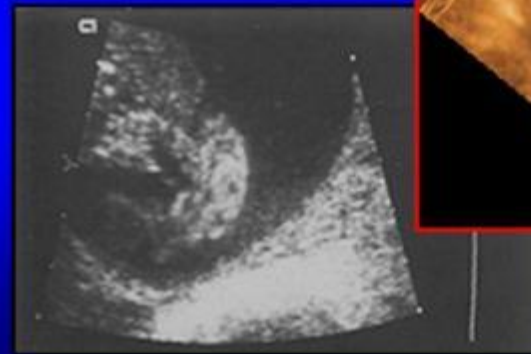90

## Gastroschisis



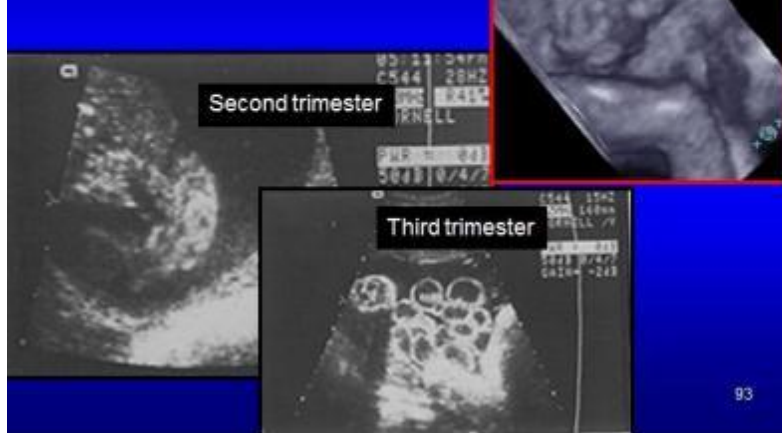
91

## Gastroschisis



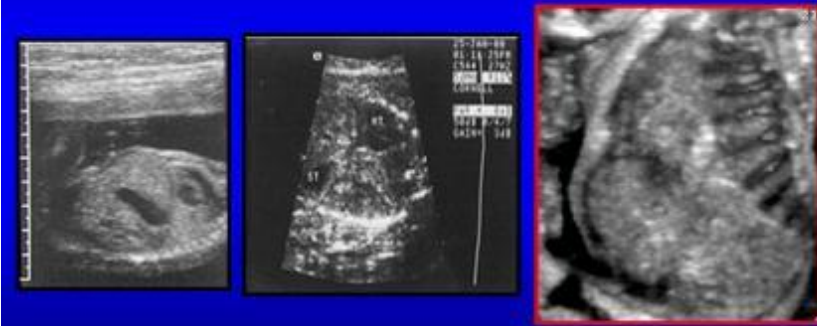
92

## Gastroschisis



93

## Congenital Diaphragmatic Hernia



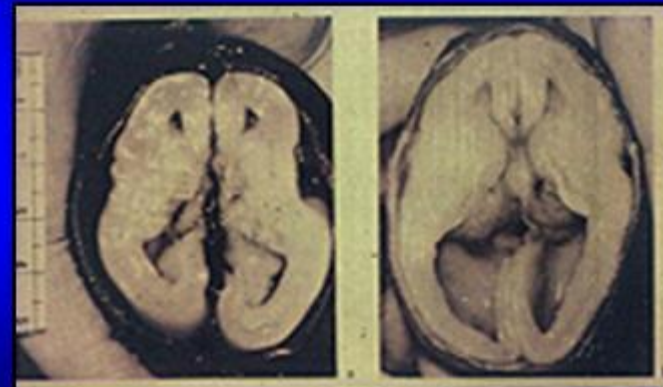
94

## The Ultrasound Diagnosis of Fetal Anomalies: An Overview

- Absence of a normally present structure
- Presence of an additional structure
- Herniation through a structural defect
- **Dilation behind an obstruction**
- Abnormal biometry
- Abnormal fetal motion

95

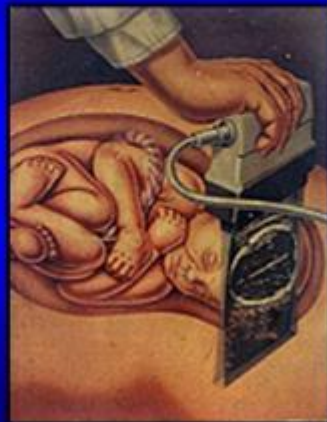## Hydrocephalus



96

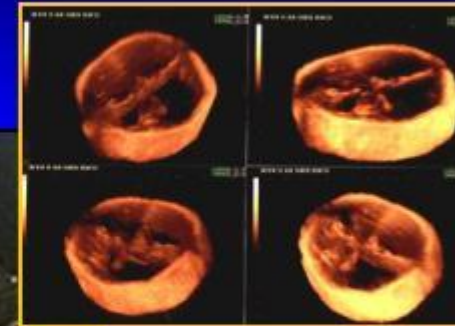
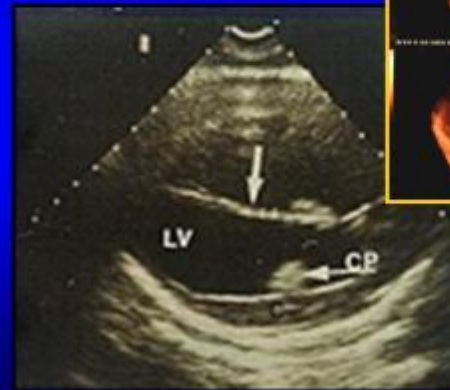

## Hydrocephalus: Ultrasound Diagnosis



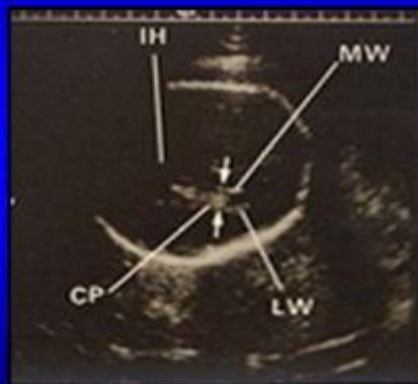
97

## Hydrocephalus



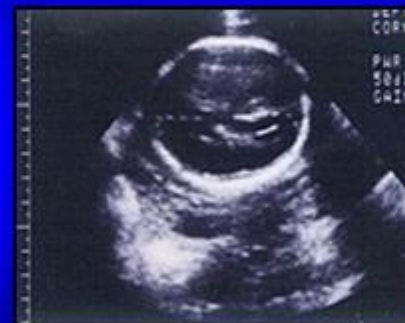98

## Atrium of the Lateral Ventricle



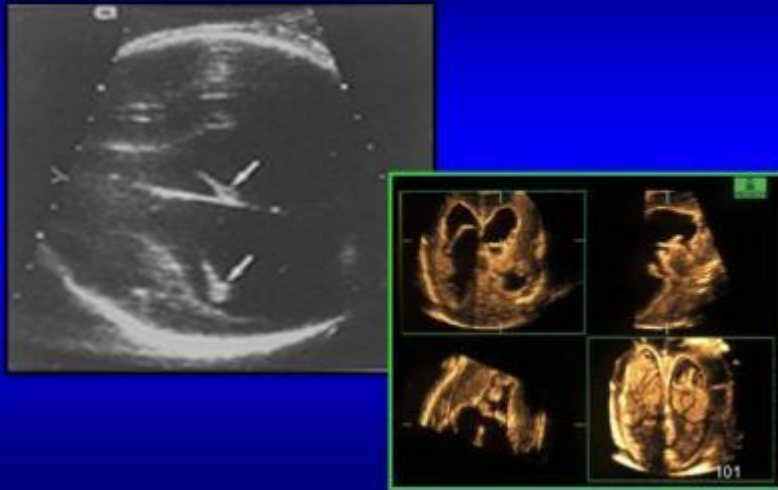
99

## Ventriculomegaly



100

## Hydrocephalus

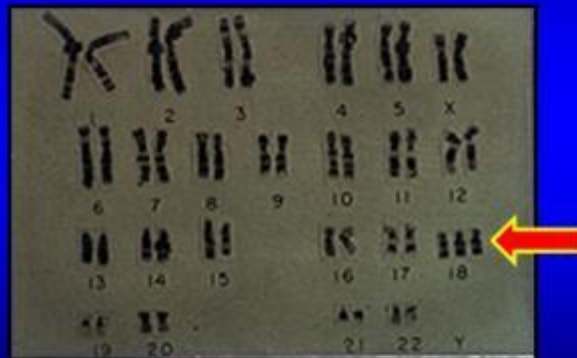

## Hydrocephalus

- Detailed sonographic evaluation
- Fetal echocardiography
- Amniocentesis for fetal karyotype

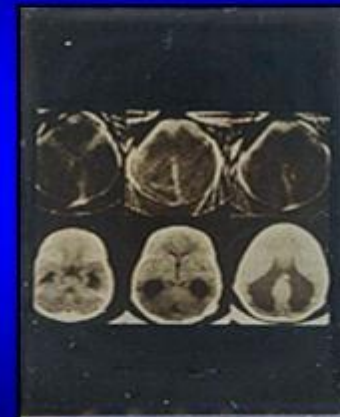
102

## Evaluation of Hydrocephalus: Fetal Karyotype



103

## Hydrocephalus



104

## Hydrocephalus: Outcome

- Dependent on etiology
- Increased frequency of mental retardation and early death
- Substantial possibility of normal, even superior intelligence

105

## Hydrocephalus

### Management Options

Dependent on gestational age at the time of diagnosis and the association of other anomalies

106

## Hydrocephalus Management

- Before 24 weeks → Expectant mgmt  
→ Abortion
- Before 30 weeks → Expectant mgmt  
→ Ventriculoamniotic shunting

107

## Ventriculoamniotic Shunting

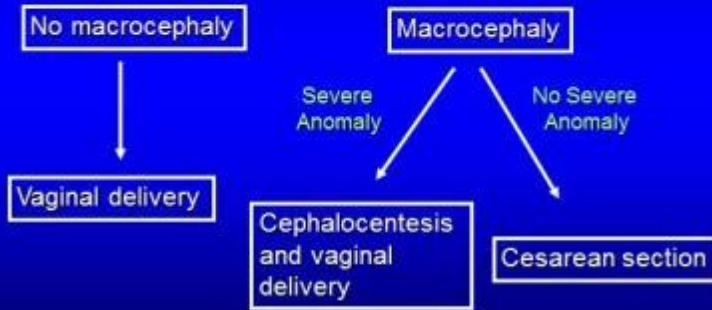


108

# Hydrocephalus:

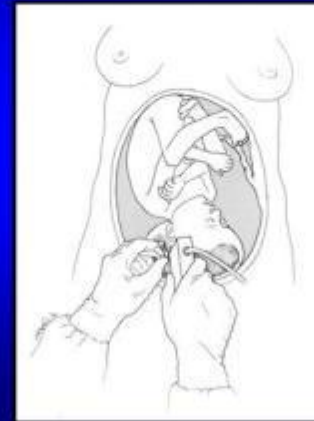## Management after 30 weeks

Expectant management until fetal lung maturity



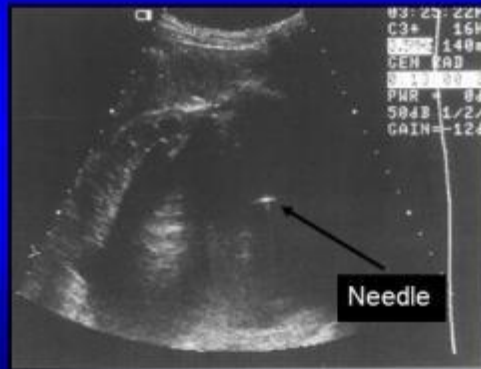109

# Cephalocentesis



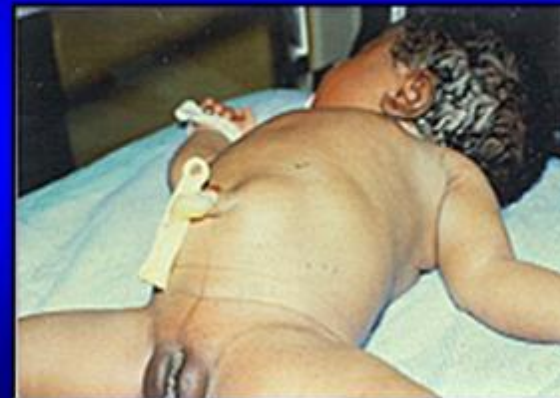110

# Cephalocentesis



111

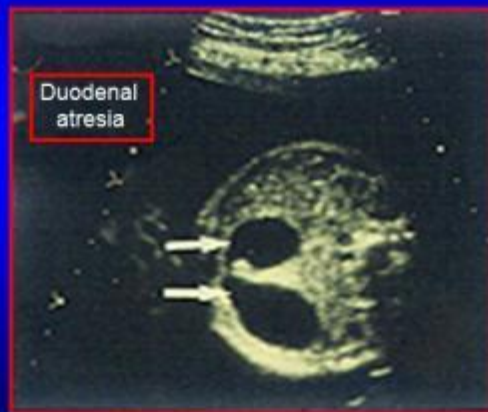# Duodenal Atresia



112

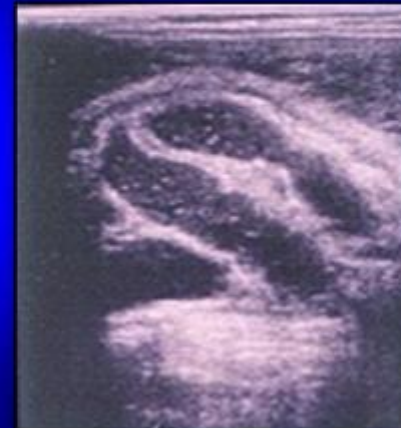## Fetal Small Bowel Obstruction

Dilation proximal to the area of obstruction



113

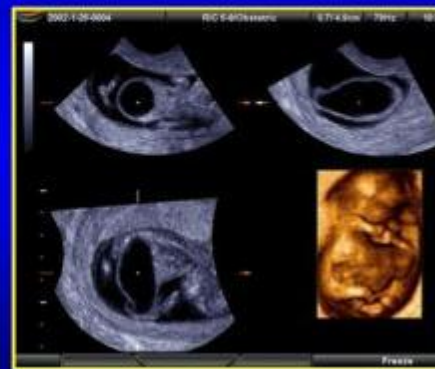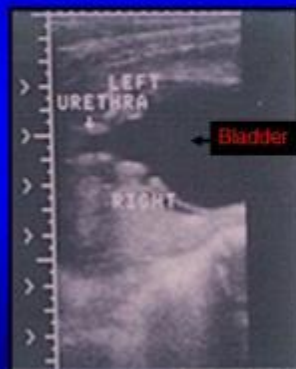## Bowel Obstruction



114

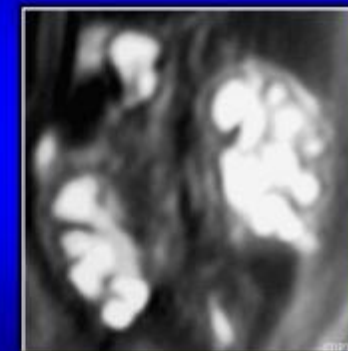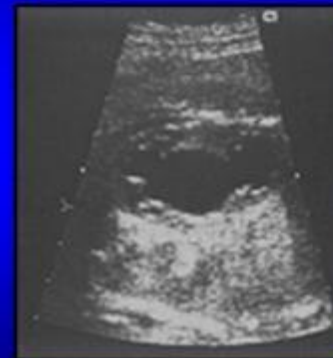## Bladder Outlet Obstruction

Obstruction to urinary flow with proximal dilation



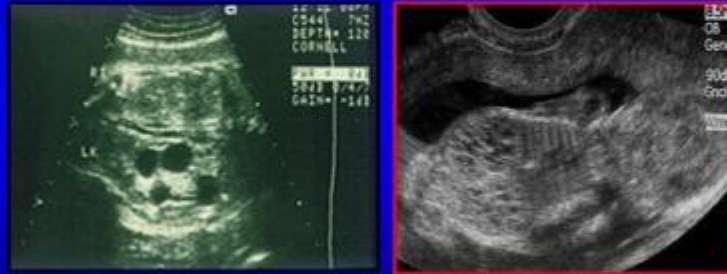
115

## Hydronephrosis



116

## Multicystic Kidney



117

## The Ultrasound Diagnosis of Fetal Anomalies: An Overview

- Absence of a normally present structure
- Presence of an additional structure
- Herniation through a structural defect
- Dilation behind an obstruction
- **Abnormal biometry**
- Abnormal fetal motion

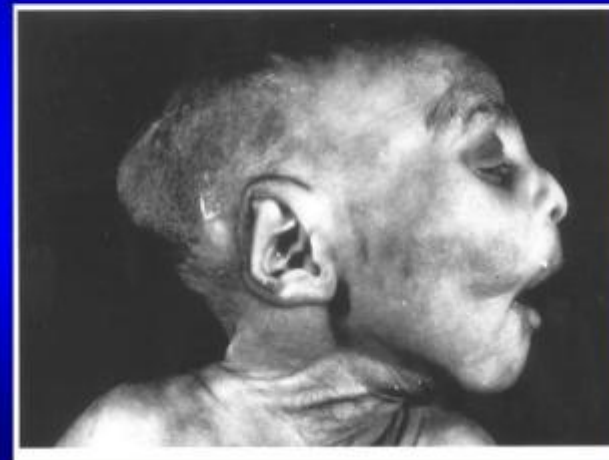118

## Microcephaly

- Strictly translated - "small head"
- Clinical importance is association with microencephaly ("small brain") or mental retardation
- Rare - Incidence based on observations at birth range from 1 in 6250 to 1 in 8500

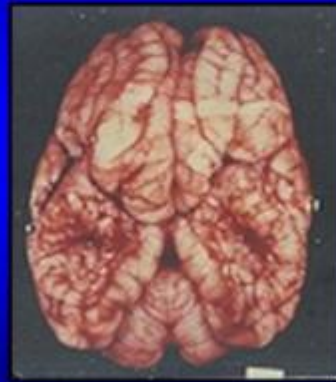
119

## Microcephaly



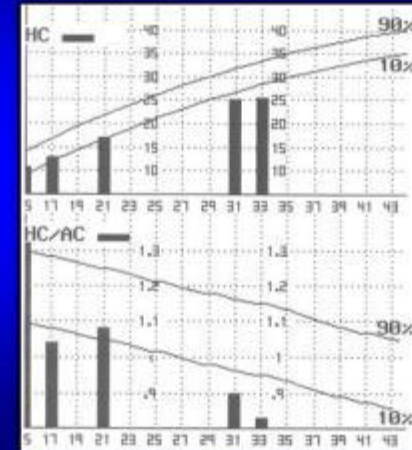
120

## Microcephaly



121

## Microcephaly



122

### Microcephaly: Diagnosis

- Normograms with means and standard deviations were derived from a longitudinal study of 695 sonographic evaluations of 45 normal fetuses
  - Biparietal diameter
  - Occipito-frontal diameter
  - Head perimeter
  - Head perimeter/abdominal perimeter
  - Biparietal diameter/femur length
  - Femur length/head perimeter

123

### Microcephaly: What is too small?

**Sensitive tests with no errors in exclusion:**

- BPD > -4 SD
- OFD > -2 SD
- HP > -3 SD
- HP/AP > -1 SD

**Specific tests with no errors in diagnosis:**

- OFD < -4 SD
- HP < -5 SD
- HP/AP < -3 SD
- FL/HP > 3 SD

*The use of multiple diagnostic tests appears necessary for both accurate diagnosis and exclusion of fetal microcephaly.*

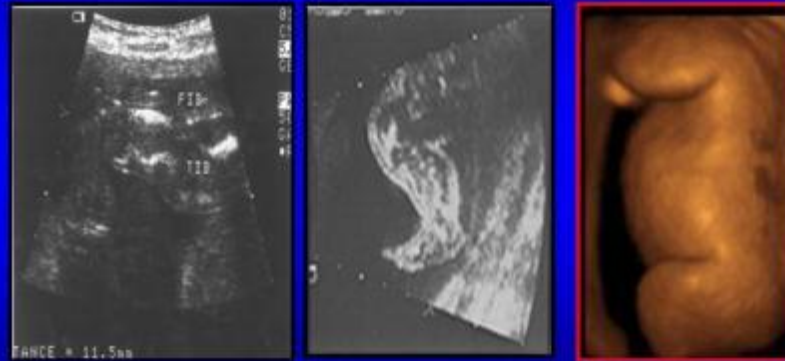
124

## Microcephaly: Outcome

- Most are mentally retarded
- The smaller the head, the worse the prognosis
- If part of a genetic syndrome, uniformly dismal outcome
- Possibility of normal intelligence even with very small head size

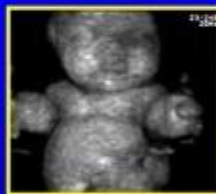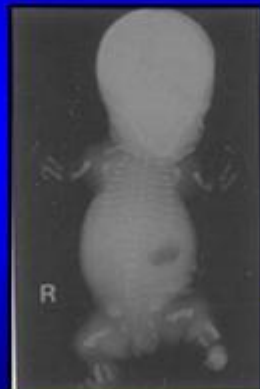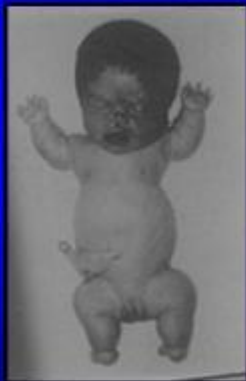125

## Skeletal Dysplasias



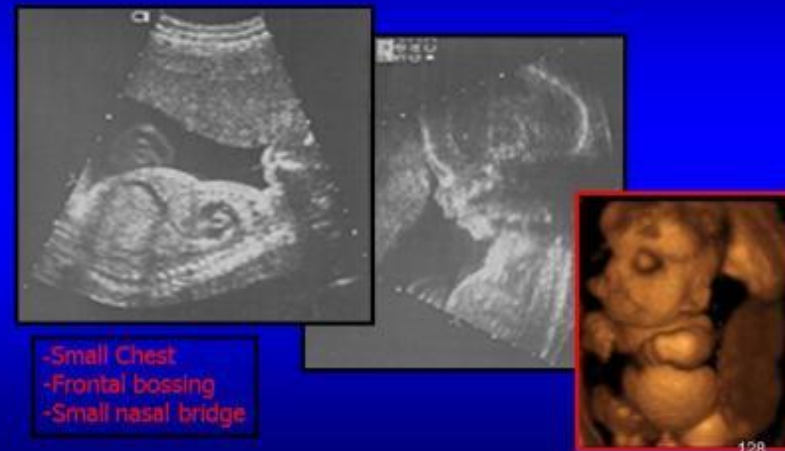
126

## Thanatophoric Skeletal Dysplasia



127

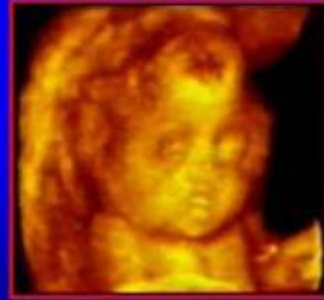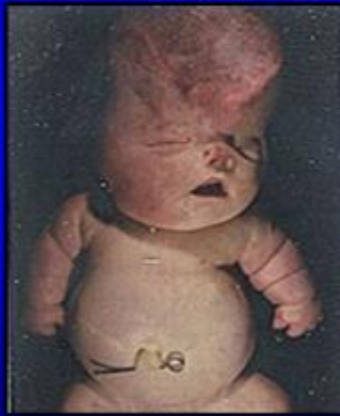## Thanatophoric Skeletal Dysplasia



128

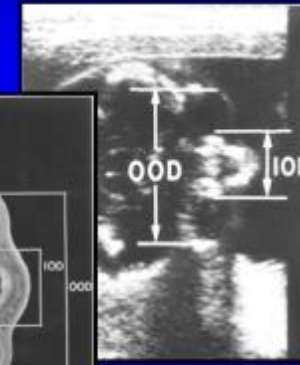
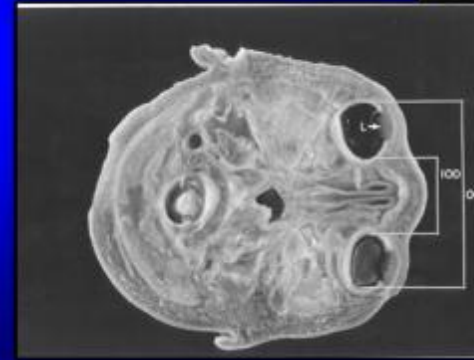
## Thanatophoric Skeletal Dysplasia Cloverleaf Skull



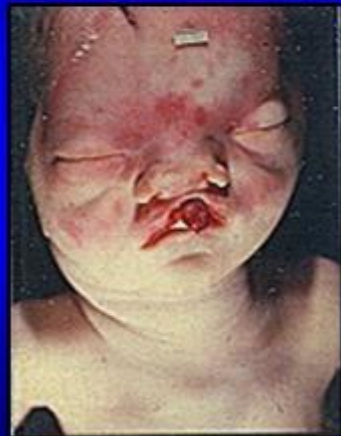129

## Orbital Distance: Evaluate for Hypotelorism



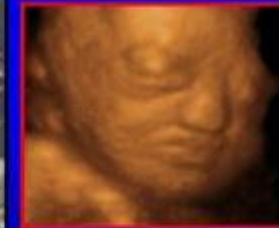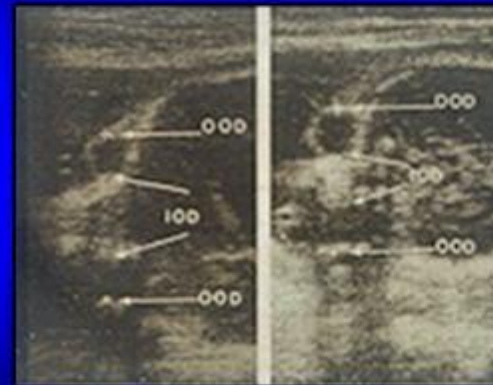
131

## Orbital Distance: Evaluate for Hypertelorism



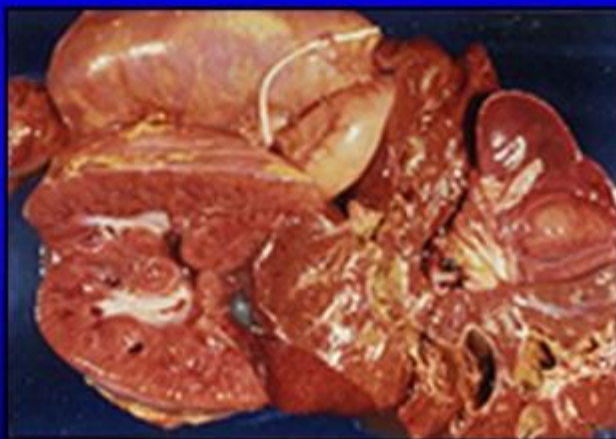132

## Hypertelorism



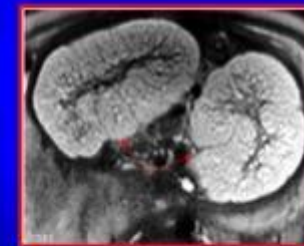
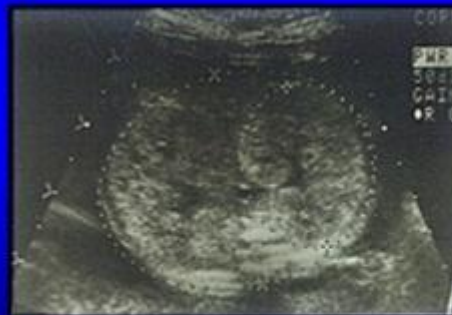133

## Polycystic Kidney Disease



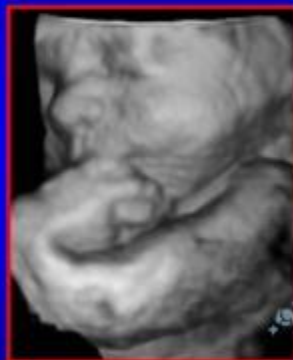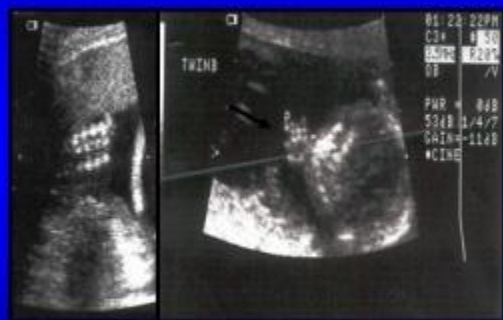
134

## Polycystic Kidney Disease



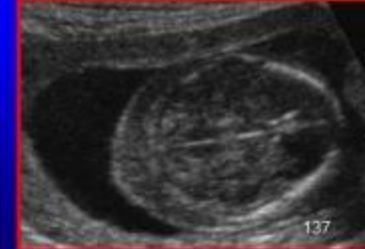
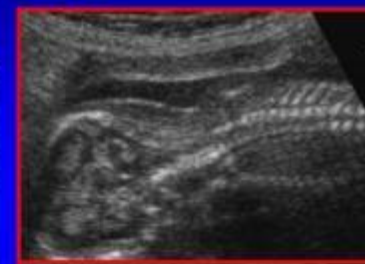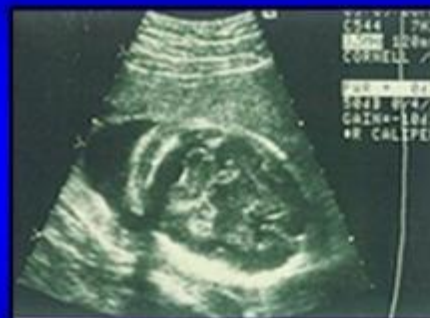135

## Hypoplasia of the Middle Phalynx of the Fifth Digit



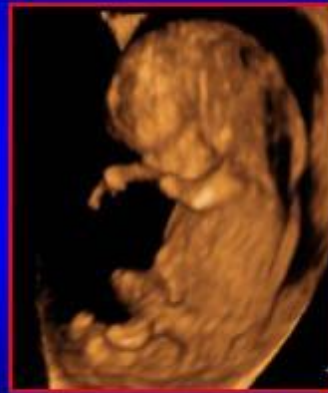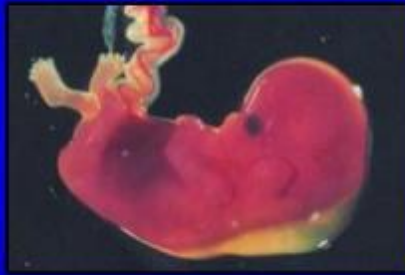136

## Nuchal Fold



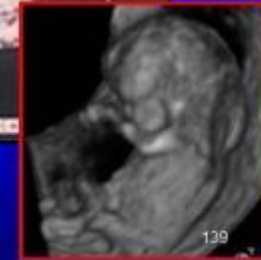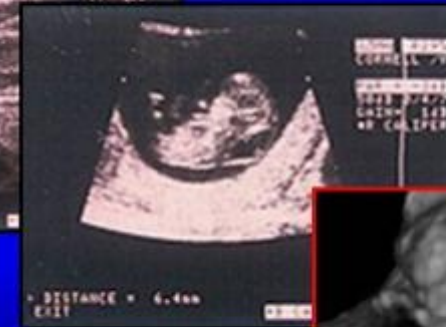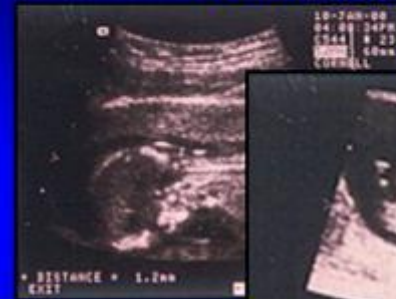137

## Nuchal Translucency



138

## Nuchal Translucency



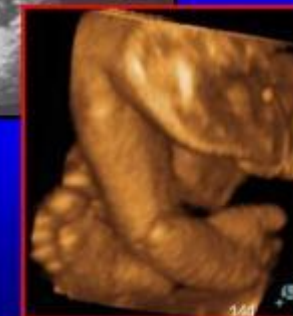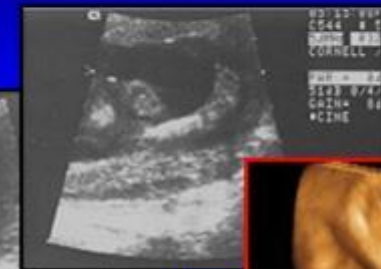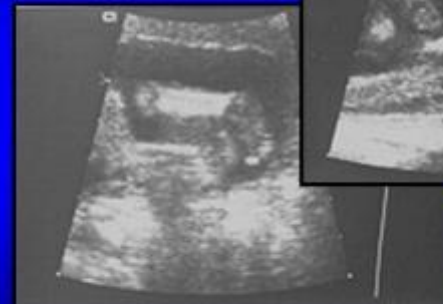
139

## The Ultrasound Diagnosis of Fetal Anomalies: An Overview

- Absence of a normally present structure
- Presence of an additional structure
- Herniation through a structural defect
- Dilation behind an obstruction
- Abnormal biometry
- Abnormal fetal motion

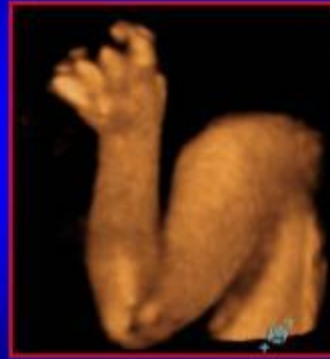
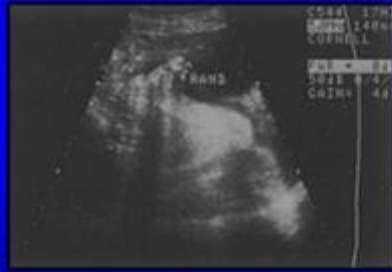140

## Clubfoot



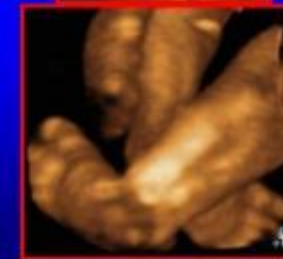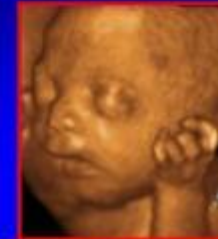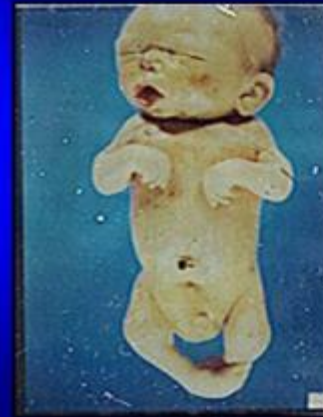140

## Arthrogryposis



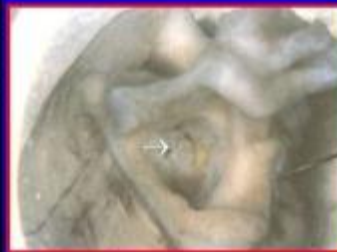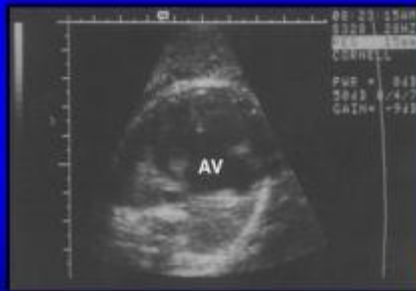142

## Arthrogryposis



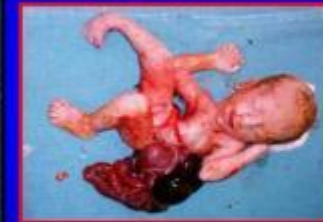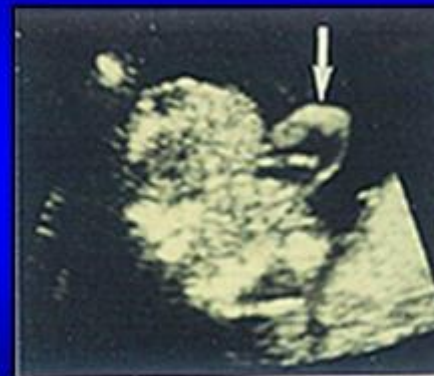143

## Endocardial Cushion Defect: AV Canal



144

## Ectopia Cordis



145

## The Ultrasound Diagnosis of Fetal Anomalies: An Overview

- Absence of a normally present structure
- Presence of an additional structure
- Herniation through a structural defect
- Dilation behind an obstruction
- Abnormal biometry
- Abnormal fetal motion

146

## Anomalies that Should Not Be Missed by Ultrasound

Frank A. Chervenak, MD

 **New York Weill Cornell Medical Center**  
Weill Cornell Medical College  
New York-Presbyterian Hospital



Jan Donald University  
Ho Chi Minh City, Vietnam  
March 2011

147